
STUDY OF THE SIZE OF THE CORONOID PROCESS OF MANDIBULE

Svetlana JovevskaFaculty of Medical Sciences, University "Goce Delcev" - Stip, Republic of N. Macedonia
svetlana.jovevska@ugd.edu.mk**Sanja Baldzieva**Faculty of Medical Sciences, University "Goce Delcev" - Stip, Republic of N. Macedonia
sanja.baldzieva@ugd.edu.mk

Abstract: The mandible serves as an important structure in relation to mastication as all the muscles of mastication are attached to it. The Coronoid process is the anterior bony projected part of ramus of mandible giving attachment to two important muscles of mastication. The aim of our study was to observe the variation in the size of coronoid process in relation to its side (laterality), shape, age and sex. The material for this study comprised of **80 (160 sides)** dry human mandibles. The age and sex differentiating criteria were detailed in materials and methods. The size of coronoid process was found to be approximately 1.5 mm longer on the right side than on the left side; 0.01 mm longer in males than females and 0.01 mm longer in dentulous than in edentulous. Triangular coronoid process was found to be the longest followed by round and then hook shaped. Male hormonal impact on muscle growth, bone remodeling and psychology probably lead to enhanced functional stress on mandible due to mastication as compared to that in females. Pterygoid muscles are involved mainly in side to side movement and Masseter-Temporalis (M-T) component in the robust vertical thrust during mastication for crushing. The condyloid process is for pterygoid and M-T-Coronoid Lever complex engenders the proportionate sexual dimorphism as observed in this study. Poor crushing activity in the edentulous is also corroborated in our observation. This comparative study is a pioneer study which will be beneficial for the Anthropologists, Forensic scientists and Reconstructive surgeons.

Keywords: Coronoid process, Hook, Mandible, Round, Triangular.

INTRODUCTION

The Mandible or the submaxilla is a "U" shaped bone forming the lower jaw, articulating with the temporal bone on either side. It bears a curve shaped body with two rami. Each ramus consists of two processes – coronoid and condylar. Coronoid process is a beak like projection flattened from side to side at the antero-superior aspect of the ramus. In Greek, "korone" means "like a crown". In lower animals separate coronoid bones are present which articulate with the splenial, angular, suprangular bones etc. to form a common "dentary bone" which is homologous to mandible in humans. In humans, there is another coronoid process present in ulna and a "coronoid fossa" in humerus. The largest portion of temporalis muscle is attached to the apex, whole of the medial surface and anterior part of lateral surface of the coronoid process. Rest of the lateral surface provides attachment to anterior fibres of masseter. These two are important muscles of mastication which show morpho-functional dependence. Several authors have described the various shapes of coronoid process. According to Issac B1, Vipul 2 and Tanveer A3, the process is triangular, hook and rounded whereas Schafer 4 described it as beak shaped. The shape and size of coronoid process is influenced by dietary habit, genetic constitution, hormone and mainly by temporalis muscle activity. Coronoid process enlargement may be seen in some pathological conditions like *osteochondroma*, exostosis, osteoma and other developmental anomalies. Hernandez-Alfaro F5 noticed a new joint between enlarged coronoid process and zygomatic bone (Jacob's disease) which causes restriction during mouth opening. Though fracture of mandible is common, but coronoid fracture incidence is rare (2%) and requires no treatment unless impingement on the zygomatic arch is present. Coronoid process hyperplasia is a very rare cause of mandibular hypomobility. So, it is usually underdiagnosed, but a thorough background anatomical knowledge can help in examining the patient clinically and radiologically. This ultimately will help in the line of management and a better clinical outcome. Coronoid process is a cartilaginous type of bone which can be removed intra-orally without any functional deficiency and facial disfigurement for reconstruction of orbital floor deformities, alveolar defects, paranasal sinus augmentation, non-union fracture of mandible, osseous defects reconstruction and other repairing procedure in cranio-maxillo facial surgeries. Various morphological features of mandible show changes in reference to age and sex. It acts as an anthropological marker for detection of races. The present study was undertaken to determine the size of coronoid process in relation to the side, age and sex and compare it with its shape.

MATERIALS AND METHODS

The present study was conducted on 80 dry human mandibles (54 males and 26 females). Determination of sex was done according to the following criteria:

Criteria	Male	Female
Gonial eversion	Marked	Slight
Chin	Square	Rounded
Muscular impression	More prominent	Less prominent

Bones collected were then grouped into two categories: **Category I – Dentulous:**

- Third molar erupted,
- Mental Foramen in between the upper and lower border of the body

Category II – Edentulous:

- Resorption of alveolar margin,
- Mental Foramen towards upper margin.

Exclusion criteria: Any mandible broken, asymmetrical or deformed was excluded from the study.

III.Observation:

Out of the 80 mandibles, 40 were Dentulous and 40 were Edentulous. The shape of coronoid process was classified into 3 types: 1. Triangular- tip pointing directly upwards 2. Rounded- tip rounded 3. Hook- tip pointing backwards
The length of the coronoid process was taken from the line tangential to the deepest part of mandibular notch to the apex as shown in the figure below. It was measured by using a divider and a scale.

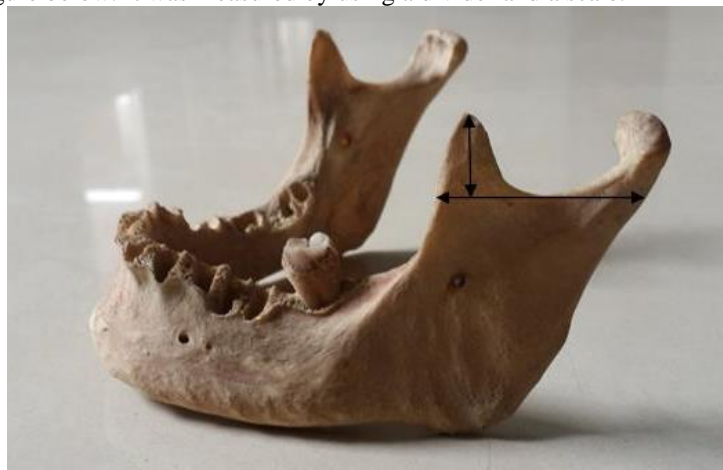

Fig.1. Measurement of triangular coronoid process

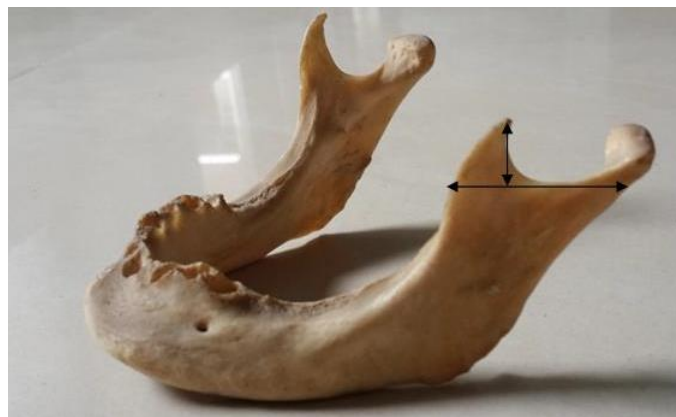

Fig.2. Measurement of hook shaped coronoid process

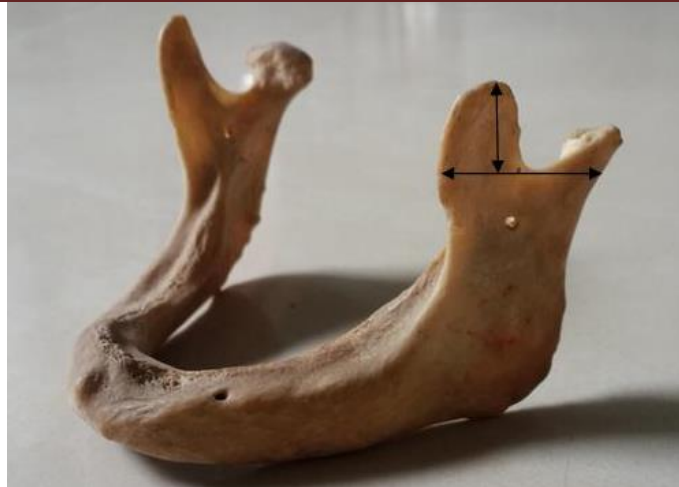

Fig.3. Measurement of round coronoid process

	<i>Right (in mm)</i>	<i>Left (in mm)</i>
Triangular	15.277	13.899
Round	15.259494	13.918
Hook	15.25675676	13.90540541
Average in Males	15.26875	13.925
Average in Females	15.2594936	13.88607
Average in Dentulous	15.28875	13.925
Average in Edentulous	15.28476821	13.89403974

Table No. 1. Average measurement of Coronoid Process in 80 dry human mandibles

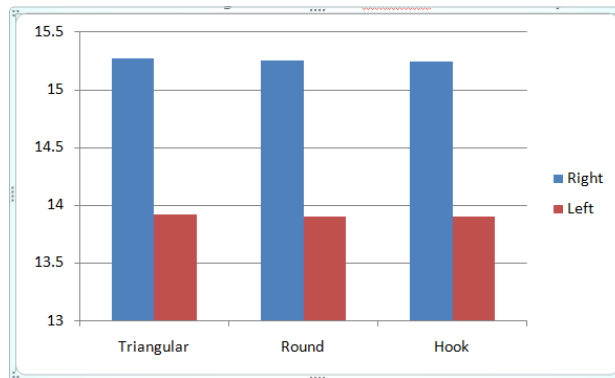


Fig.4. Variation in size in relation to side

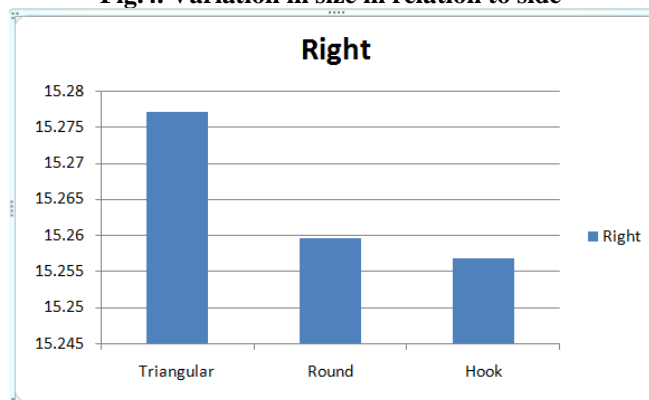


Fig.5. Variation in size on Right side

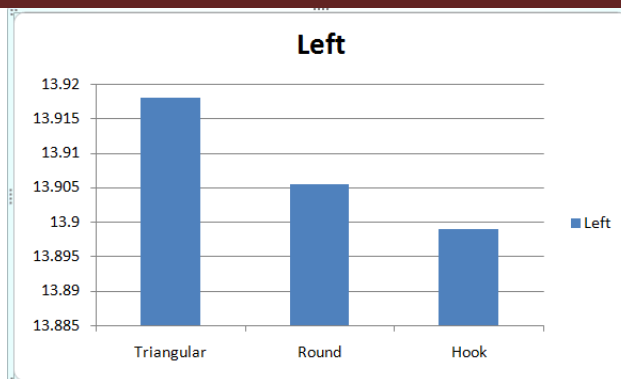


Fig.6. Variation in size on Left side

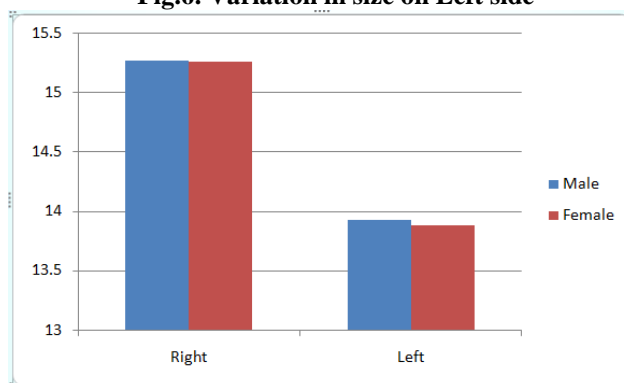


Fig.7. Variation in relation to sex

DISCUSSION

The size of coronoid process was found to be approximately 1.5 mm longer on the right side than on the left side; 0.01 mm longer in males than females and 0.01 mm longer in dentulous than in edentulous. Triangular coronoid process was found to be the longest followed by round and then hook shaped. Apart from the involved genetic factor, the functional factors necessitate the right coronoid process to be longer than the left. This is vindicated by the data from this study in the mandibles of the dentulous and of the males. Male hormonal impact on muscle growth, bone remodeling and psychology probably lead to enhanced functional stress on mandible due to mastication as compared to that in females. Pterygoid muscles are involved mainly in side to side movement and Masseter-Temporalis (M-T) component in the robust vertical thrust during mastication for crushing. The condyloid process is for pterygoid and M-T-Coronoid Lever complex engenders the proportionate sexual dimorphism as observed in this study. Poor crushing activity in the edentulous is also corroborated in our observation. However, the lateralization of the M-T-lever effect largely depends upon the individual masticatory behavior. It seems probable that the larger population reflexly use the right side of the jaw for crushing as compared to that in left which is reflected in the enlarged Right coronoid. This is also reflected in the shape of the coronoid process as larger stress helps it to get remodeled as triangular with pointed tip, less stress for rounded and further less being the hooked coronoid process.

CONCLUSION

The data provided by the present study will help the dental and maxillo-facial surgeons in planning graft implants and reconstructive surgeries. More studies involving larger sample size and other group of population is desirable for better correlation of age and sex change in size of coronoid process.

REFERENCES

- Abu-Taleb, N.S., & El Beshlawy Taleb, D.M., (2015) Mandibular ramus and gonial angle measurements as predictors of sex and age in an Egyptian population sample: A digital panoramic study. *J Forensic Res*;6:5.
- An, J., Jia, P., Zhang, Y., Gong, X., Han, X., & He, Y., (2015) Application of biodegradable plates for treating pediatric mandibular fractures. *J Cranio-Maxillofac Surg*;43(4):515–520.

-
- Duric, M., Rakocevic, Z., & Donic, D., (2005)The reliability of sex determination of skeletons from forensic context in the Balkans. *Forensic Sci Int.*;147(2-3):159-64.
- Dayal, M.R., Spocter, M.A., & Bidmos, M.A., (2008)An assessment of sex using the skull of black South Africans by discriminant function analysis. *Homo.*;59(3):209-221.
- Guyomarc'h P, & Bruzek J. (2011)Accuracy and reliability in sex determination from skulls: A comparison of Fordisc 3.0 and the discriminant function analysis. *Forensic Sci Int.*;208(1-3):180.
- Loth, S., Iscan, Y. *Anthropology.* (2000)Sex Determination. In: *Encyclopedia of Forensic Sciences.* Edited by Siegel J, Knupfer G, Saukko P: Academic Press.:252-260.
- Larheim, T.A., & Svanaes, D.B., (1986) Reproducibility of rotational panoramic radiography: mandibular linear dimensions and angles. *Am J Orthod DentofacialOrthop.*;90(1):45-51.
- Okşayan, R., Asarkaya, B., Palta, N., Şimşek, İ., Sökücü, O., et al. (2014) Effects of edentulism on mandibular morphology: evaluation of panoramic radiographs. *ScientificWorldJournal* 2014: 254932.
- Pradhan, S., Bara, D. P., Patra, S., Nayak, S., & Mohapatra, C., (2014)Anatomical Study of Various Shapes of Mandibular Coronoid Process in Relation to Gender &Age; *IOSR Journal of Dental and Medical Sciences*; Volume 13, Issue 8 Ver. II, PP 09-14
- Sunita, N., Swagatika, P., Dibya, P. B., Smita, P., (2015)Bilateral elongated coronoid process: a case report; *IOSR Journal of Dental and Medical Sciences*; Volume 14, Issue 5 Ver. VI, PP 61-63
- Thakur, M., Reddy, K.V., Sivaranjani, Y., & Khaja, S., (2014)Gender determination by mental foramen and height of the body of the mandible in dentulous patients a radiographic study. *J Indian Acad Forensic Med*;36:13-18.
- Yang RT, Lv K, Zhou HH, Li Z, Li ZB. (2015)Resorbable plates for the fixation of isolated mandibular angle fracture. *J Craniofac Surg.*;26(2):447–448.