
ACUTE URINARY RETENTION CAUSED BY HUGE URETHRAL CARUNCLE

Ilbert AdemiGeneral City Hospital “Ferid Murad”, Department of surgery with urology- Gostivar, Republic of N. Macedonia, ylberademi@live.com**Adnan Vrajnko**General City Hospital “Ferid Murad”, Department of surgery with urology- Gostivar, Republic of N. Macedonia, dr.adnanv@gmail.com**Majlinda Ademi**Faculty of Medical Sciences, “Goce Delcev” University-Stip, Republic of N. Macedonia, majlindaademi@live.com

Abstract: The female urethra is about 4 cm long and 8 mm in diameter. It is slightly curved and lies beneath the pubic symphysis just anterior to the vagina. Urethral lesions are important diagnostic tools in female urology. A urethral caruncle is a benign vascular tumor usually originating from the rear lip of the external urethral meatus, respectively, usually arise from the posterior lip of the urethral meatus and often observed in postmenopausal women. Although the etiology of urethral caruncles is still undetermined, they are the most common benign tumors of the female urethra including inflammatory polyps, cysts (Bartholin's), prolapse of the urethra, urethral cancer, and diverticulum. Most cases are frequently asymptomatic, but, sometimes patients feel a lump or bleeding at the urethral meatus and sometimes it might cause acute urinary retention. Urethral caruncle is not included within the list of bladder overdistension causes in women. We present a huge urethral caruncle as a rare cause of acute urinary obstruction in a 51 year old woman, who asked for medical help on our emergency unit. The family referred that she was unable to urinate for the last 12h. The physical examination revealed bladder overdistension (globus vesicalis) and acute urinary retention. The patient's history revealed a gradual reduction in urine flow for the last year and the presence of blood stains on her underwear over the past month. On a pelvic examination, there was a 3 × 2.5 cm dark red mass protruding circumferentially from the urethra that was soft on palpation and originating from the posterior lip of the external meatus, was found during catheterisation. The case was evaluated with physical examination and the bladder was evacuated with a 12-Fr urethral catheter. In total, 1200 cc residual urine was removed. She had normal preoperative serum blood urea nitrogen (BUN) and creatinine levels. Before the surgical treatment we performed urethrocytoscopy which was normal. The patient was placed in the dorsolithotomy position. The caruncle was excised under general anesthesia. The lesion was totally resected (excision) and settled with 4-0 absorbable sutures and an 18 French (F) Foley silicon catheter was placed for urine drainage. There were no complications. The patient was discharged on the third postoperative day, the urethral catheter was removed on the seventh day and afterward the patient started to urinate easily. After surgical excision the histopathological report confirmed urethral caruncle. Local estrogen creams were also applied during the postoperative period. The postoperative period was uneventful and no signs of residual complaints were observed after 12 months of follow-up.

Keywords: urethral caruncle, acute urinary retention, globus vesicalis, urethrocytoscopy

INTRODUCTION

Urethral caruncle is a benign vascular tumor, which usually arises from the posterior lip of the urethral meatus. It represents the most common lesion of the female urethra and occurs primarily in postmenopausal women (Cimantepe, E. et al., 2006). Giant urethral caruncle presenting as genital prolapsed (Coban, & Biyik, 2014) and as a cause of acute urinary retention (Hizli, F. et al., 2014) has been described in literature. Urethral caruncle consists of vascular connective tissue loosely surrounded with transitional and squamous epithelial cells. The most important risk factor in its etiology is hypoestrogenemia (Chiba, M. et al., 2015). Urethral caruncles often arise from the lower lip of the urethral meatus and are rarely greater than 1 cm in diameter. Although the etiology of urethral caruncles is still indefinite, they are the most common benign tumors of the female urethra (Altinoluk, B. et al., 2010). We present huge urethral caruncle as a rare cause of acute urinary obstruction in a 51 year old women.

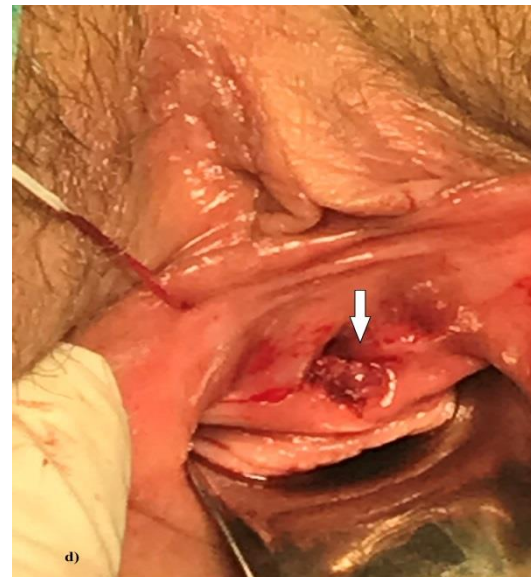
CASE REPORT

A 51 year old female patient presented to the emergency unit of our hospital. The family referred that she was unable to urinate for the last 12h. The physical examination revealed bladder overdistension (globus vesicalis) and acute urinary retention. The patients history revealed a gradual reduction in urine flow for the last year and the presence of blood stains on her underwear over the past month. On a pelvic examination , there was a 3 × 2.5 cm dark red mass (Figure 1) protruding circumferentially from the urethra that was soft on palpation, originating from the posterior lip of the external meatus, was found while inserting urethral catheter.

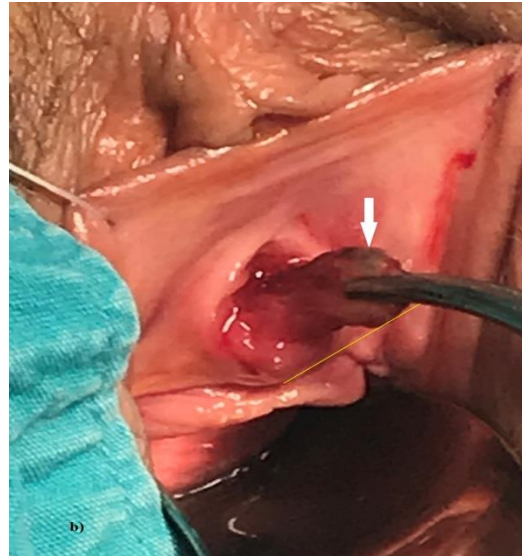
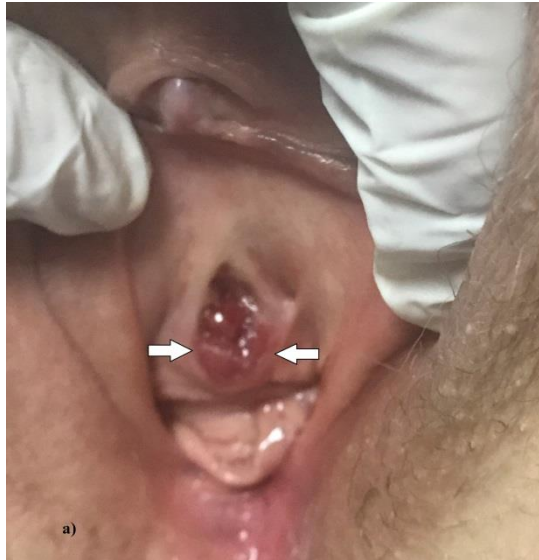
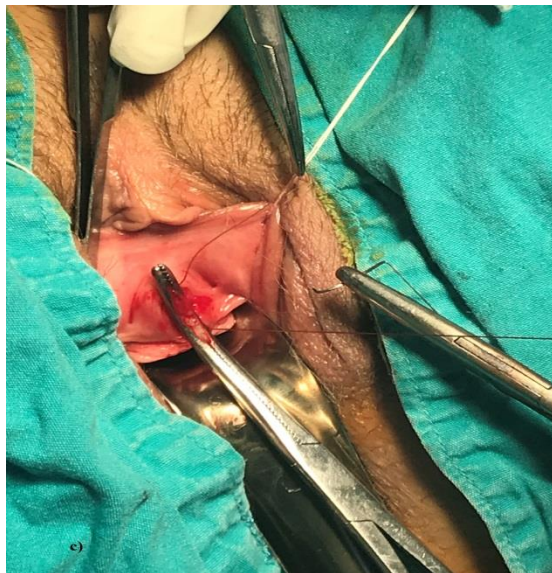Figure 1: a) Urethral caruncle during pelvic examination;

b) Urethral caruncle before excision



c) Suture of the base of mucosa

d) Meatus of urethra after total excision

Only a 12-Fr urethral catheter could be placed due to the meatal obstruction caused by the urethral caruncle. In total, 1200 cc residual urine was removed. Initially, an 17-Fr urethrocystoscopy was performed following the urethral dilatation under local anesthesia. The urethrocystoscopy was normal and the symptoms were associated with the

urethral caruncle. She had normal preoperative serum blood urea nitrogen (BUN) and creatinine levels. The vulvar skin and vaginal mucosa had normal appearance. The next day, the patient was placed in the dorsolithotomy position under general anesthesia. The lesion was totally resected (excision) and settled with 4-0 absorbable sutures and an 18 French (F) Foley silicon catheter was placed for urine drainage. There were no complications. The patient was discharged on the third postoperative day, the urethral catheter was removed on the seventh day and afterward the patient started to urinate easily. Microscopic examination of the specimen revealed a transitional epithelium covering the stroma with inflammation, extravasated red blood cells and prominent vascularity observed. Histopathologically was reported as a urethral caruncle.. Local estrogen creams were also applied during the postoperative period. The postoperative period was uneventful and no signs of residual complaints were observed after 12 months of follow-up.

DISCUSSION

Urethral caruncle was first described by Samuel Sharp in 1750 . This occurs mainly at the posterior lip of the urethra, and the exact aetiology is still uncertain . But two possibilities suggested as aetiological factors are chronic inflammation and oestrogen deficiency. These can be as seen pedunculated or sessile lesions. They are divided in two types according to the clinical features as true caruncles (a vascular papilloma) and pseudocaruncles (a granuloma) . Histology has showed either transitional or squamous cell type as the overlying epithelium. Patients may be asymptomatic and could find this as an incidental finding or they may present with symptoms such as dysuria, bleeding per vagina, haematuria, a mass protruding through vagina, and acute retention of urine (Gamage, & Beneragama, 2018). Urethral caruncles are benign lesions of the distal urethra which have been most commonly described in post-menopausal women. Although caruncles are usually benign, they should be surgically excised and histopathologically examined since they may be the indicators of lymphoma, clitoral venous thrombosis, urethral thrombosis, pseudoneoplastic lesions, urethral polyps, malign melanoma, intestinal heterotypic, angiomatous lesions, and diastolic urethral stenosis (Coban, & Biyik, 2014). Although the caruncles are considered as benign tumors, they need to be treated with surgical intervention; pathologic specimens should carefully be evaluated for having any malignancy and treatment plans established based on the results. When the lesion is atypical in view or behavior, surgical excision may be required to exclude other entities (Hizli, F. et al., 2014). In one published case, huge urethral caruncle affected a young couple's sexual life. Urethral caruncle caused an obstruction by its mass effect. The patient's husband experienced difficulty to penetrate the vagina and since the lesion did not regress with many medical treatment modalities, he divorced the young female. However urethral caruncle causing divorce is quite interesting (Altinoluk, B. et al., 2010). Although urethral caruncles do not usually result in complaints other than cosmetic distress, they sometimes lead to bleeding observed as blood stains on underwear, painful urination with an intermittent split stream, and acute urinary retention (Tanagho, E.A. et al., 2008). Large caruncles blocking the urinary flow should be surgically excised (Rovner E., 2007). Urethral caruncles occur commonly in middle aged and elderly women and present as solitary, soft, raspberry-like pedunculated tumours, about the size of a pea, attached to the posterior urethral wall near the external urethral meatus (Tipfat, R. C., 1992). Urethral caruncles, more often they are seen in the postmenopausal (Yakasai, I. A. et al., 2012) women, and only few cases are reported in young girls (Yakasai, I.A. et al., 2012; Becker, L. E., 1975; Kyung Kim, K. et al., 1993). Urethral caruncles are very rare in males. The size may vary from 1-2 mm to 1-2 cm (Yakasai, I. A. et al., 2012). A variety of lesions have been reported that mimicked urethral caruncles and some of these include: melanoma of urethra (Nakamoto, T. et al., 2007)], tuberculosis (Indudhara, R et al., 1992; Singh & Hemal, 2002), and urethral leiomyoma (Sarooha, V. et al., 2010). Urethral caruncles in 32% of cases are asymptomatic and usually are found in postmenopausal women (Conces, M .R. et al., 2012). About 5% of caruncles proved to be tumors in a 46-year-old study that is still quoted by every author who writes about caruncle (Marshal. F.C et al., 1960). Of 400 clinical caruncles, biopsy revealed urothelial cancer in 1.5% and carcinoma in situ in another 0.75%. The management of a urethral caruncle consists of surgical excision, cryotherapeutic ablation or, conservatively, local application of estrogen and steroid creams (Singh, & Hemal, 2002). Surgical management is reserved for cases with severe symptoms, where conservative management has failed or where the diagnosis is uncertain. Several methods for surgical excision are described in the literature but the key steps include cystoscopy followed by insertion of a urethral catheter. Stay sutures can then be placed in the proximal epithelium to prevent mucosal retraction and meatal stenosis. The lesion can then be excised and the edges over-sewn with 3-0 or 4-0 absorbable sutures (Hall, et al., 2017; Venyo, A., 2012). The ligation method described by Park and Cho (Park, & Cho, 2004) involves placement of a ligature at the base of the caruncle and allowing it to atrophy and fall off over a period of weeks. These authors state that the apparent advantage of this method is that it can be done without general anaesthetic. Following excision, the recurrence rate

in one series of 41 cases was 7% (Conces, M.R. et al., 2012) and the complications include postoperative bleeding, urethral retraction, recurrence or urethral stricture (Hall, et al., 2017).

CONCLUSION

A urethral caruncle is rare among the causes of urinary retention. There is limited information on this subject. Great or persistent caruncles and those with an abnormal view should be surgically treated aggressively and carefully evaluated and pursued for the presence of any potential malignancy.

REFERENCES

- Altinoluk, B., Gul, A. B., Resim, S. & Ciralik, H. (2010). Huge urethral caruncle causing divorce in a young female: case report. *Turkiye klinikleri J Med Sci*; 30 (4).
- Becker, L. E. (1975). Urethral caruncle: a herald lesion for distal urethral stenosis? *Journal of the National Medical Association*, vol. 67, no. 3, pp. 228–230
- Chiba, M., Toki, A., Sugiyama, A., Suganuma, R., Osawa, S. & Ishii, R (2015). Urethral caruncle in a 9-year-old girl: A case report and review of the literature. *J Med Case Rep* 9:71.
- Cimentepe, E., Bayrak, O., Unsal, A., Koç, A., Ataoğlu, O. & Balbay, M. D. (2006). Urethral adenocarcinoma mimicking urethral caruncle. *Int Urogynecol J Pelvic Floor Dysfunct*; 17:96-8
- Coban, S. & Bıyık, I. (2014). Urethral caruncle: Case report of a rare acute urinary retention cause. *Can Urol Assoc J*; 8:E270-2
- Conces, M. R., Williamson, S. R., Montironi, R., Lopez-Beltran, A., Scarpelli, M., & Cheng, L. (2012). Urethral caruncle: clinicopathologic features of 41 cases. *Hum Pathol*. 43:1400-4
- Gamage, M. & Beneragama, D. (2018). Urethral Caruncle Presented as Premature Menarche in a 4-Year-Old Girl. *Case Reports in Pediatrics*, Volume, Article ID 3486032, 2 pages
- Hall, M. E., Oyesanya, T. & Cameron, A. P. (2017). Results of surgical excision of urethral prolapse in symptomatic patients. *Neurourology and Urodynamics*
- Hizli, F., Cetinkaya, K., Bilir, G., & Basar, H. (2014). Giant urethral caruncle presenting as genital prolapse. *Urol J*, 11:1841-3
- Indudhara, R., Vaidyanathan, S., & Radotra, B. D. (1992). Urethral tuberculosis. *Urol Int*. 48(4): 436 – 438
- Kyung Kim, K., Yeol Sin, D., & Park, H. W. (1993). Urethral caruncle occurring in a young girl. A case report, *Journal of Korean Medical Science*, vol. 8, no. 2, pp. 160-161
- Marshall, F. C., Uson, A. C., & Melicow, M. M. (1960). Neoplasms and caruncles of the female urethra. *Surg Gynecol Obstet*. 110:723-733.
- Nakamoto, T., Inoue, Y., Ueki, T., Niimi, N., & Iwasaki, Y. (2007). Primary amelanotic malignant melanoma of the female urethra. *Int J Urol*. 14(2):153 – 155
- Park, D. S., & Cho, T. W. (2004). Simple solution for urethral caruncle. *J Urol* 172(5 Pt 1):1884-5.
- Rovner, E. (2007). Bladder and Urethral diverticula. In: Wein A.J, Kavoussi L.R, Novick A.C, Partin, A.W., Peters, C. A. *Campbell-Walsh Urology 9th ed*. Philadelphia, Saunders, pp, 2361-2391.
- Saroha, V., Dhingra, K. K., Gupta, P. & Khurana, N. (2010). Urethral leiomyoma mimicking a caruncle. *Taiwan J Gynecol*. 49(4): 523 – 524
- Singh, I., & Hemal, A. K. (2002). Primary urethral tuberculosis masquerading as a urethral caruncle: a diagnostic curiosity. *Int Urol Nephrol*. 34(1): 101 – 10
- Tanagho, E. A., Brant, W. O., & Lue, T. F. (2008). Disorders of the female urethra. In: Tanagho E. A., McAnich, J. W. *Smith's General Urology. 17th ed*. San Francisco, McGrawHill pp, 638-644
- Tipfat, R. C. (1992). The urethra and penis. In: Mann, C.V, Russel, R.C.G, eds. *Short Practice of Surgery*. 21st ed. London: Chapman and Hall; 1992. p.1464.
- Venyo, A. (2012). Urethral caruncles: a review of the literature. *WebmedCentral Urology* 3(6)
- Yakasai, I. A., Aji, S. A., Muhammed, Y. A., & Abubakar, I. S. (2012). Unusual presentation of urethral caruncle in a 2 year old child: a case report, *Asian Journal of Natural and Applied Sciences*, vol. 1, no. 4, pp. 22–26.