
**CONSERVATIVE THERAPY OF PATIENTS WITH SUPERFICIAL
THROMBOFLEBITIS**

Milan Tsekov

Clinic of Vascular Surgery, Military Medical Academy-Sofia, milantsekov74@gmail.com

Mihaela Mireva

Medical College “Jordanka Filaretova”, Medicine University-Sofia, Mihaela_mirewa@abv.bg

Mariana Albert

Medical College “Jordanka Filaretova”, Medicine University-Sofia, andial@mail.bg

Abstract: Superficial vein thrombophlebitis (STP) is a common inflammatory-thrombotic process that may occur spontaneously, after a trauma or as a complication after medical or surgical interventions (1, 2, 6). In most of the cases it is a sterile inflammation of the vein wall and the surrounding tissue, accompanied by intravenous thrombosis. In the rare cases of infectious superficial thrombophlebitis, the infection is introduced inside the veins, mostly after venous manipulations, by insects, traumatism or furunculosis.

The frequency of the disease is higher at women, probably because of pregnancy and the high rate of varicosis. The superficial thrombophlebitis affects all the ages (from 18 to 87), but is most frequent between 50 and 60 years for men and women.

In a nine years period, since 01.01.2009 to 31.12.2017, 495 patients were treated by STP in Military medical Academy. They were divided in two groups. 108 (22%) patients from the first group, were admitted for surgery. The other group of 387 patients underwent conservative therapy.

The goals of therapy for superficial thrombophlebitis are to prevent progression into the deep venous system and to hasten the resolution of the inflammatory and thrombotic processes in areas already involved.

The nonsteroidal antiinflammatory and venotonical drugs, low molecular weight heparin and nonsteroidal creams for local application are the first options. In the rare cases of infectious thrombophlebitis, the antibiotics are applied. When the thrombophlebitis of the saphenous veins reaches the saphenofemoral (SFJ) or saphenopopliteal (SPJ) junction, or cloth reaches the iliac veins, the surgical treatment is suggested.

Keywords: Chronical venous disease, varicose disease, deep vein thrombosis, postthrombotic syndrome.

**КОНСЕРВАТИВНО ЛЕЧЕНИЕ ПРИ ПАЦИЕНТИ С ПОВЪРХНОСТЕН
ТРОМБОФЛЕБИТ**

Милан Цекков

Клиника „Съдова хирургия”-ВМА София, milantsekov74@gmail.com

Михаела Мирева

Медицински колеж „Йорданка Филаретова”-Медицински университет-София,

Mihaela_mirewa@abv.bg

Мариана Алберт Д.

Медицински колеж „Йорданка Филаретова”-Медицински университет-София

andial@mail.bg

Резюме: Повърхностният тромбоз (ПТФ) е асептичен възпалителен процес на венозната стена, придружен от интравенозна тромбоза. Появява се спонтанно, при травми или като усложнение при венозни приложения или хирургически интервенции. Най-често процесът е асептичен, като обхваща и перивенозната тъкан и се явява усложнение на варикозно променените повърхностни вени - 10 пъти по-често отколкото при варикозно непроменени вени.(3, 4). Случаите на инфекциозен тромбоз са редки. В тези случаи обикновено инфекцията е внесена отвън - травми, венозни манипулации, ухапвания от насекоми или по съседство (фурункул).

Честотата на повърхностен тромбоз е по-голяма при жените, поради бремеността и вероятно поради по-високата честота на варикоза на долните крайници. Засегнати са всички възрастови групи, от 18 до 87 годишна възраст, но най-много са пациентите и от двата пола между петата и шестата декада.

За девет годишен период от време, от 01.01.2009 година до 31.12.2017 година през диагностично-консултативния кабинет на ВМА и през спешният хирургичен кабинет на ВМА са преминали 495 пациенти

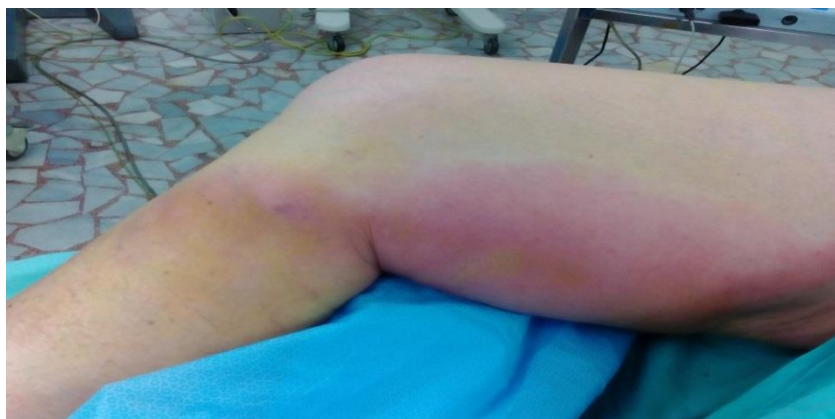с повърхностен тромбофлебит. Те са разделени на две групи. Първата група включва 387 (78%) пациенти лекувани консервативно в амбулаторни условия. Втората група включва 108 (22%) пациенти които са хоспитализирани.

Целта на лечението е да се преустанови възпалителният процес, да се предотврати разпространението на тромбозата към дълбоките вени и да се предотврати най-сериозното усложнение-Белодробната тромбоемболия (БТЕ). То се осъществява с нестероидни противовъзпалителни средства (НСПВС), венотоници, нискомолекулярни хепарини и НСПВС за локална апликация. В редките случаи на инфекциозен тромбофлебит се прилага и антибиотична терапия. Когато процесът достигне до сафено-феморалната или сафено-поплицеалната връзка, както и при прогресия на тромба в илиачните вени се налага хирургично лечение.

Ключови думи: ХВН, варикозна болест, дълбока венозна тромбоза, постфлебитен синдром.

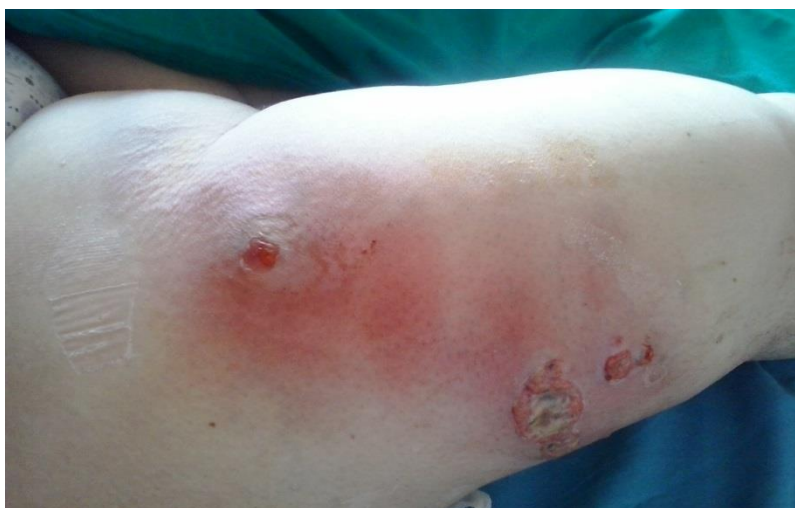INTRODUCTION

Superficial vein thrombophlebitis is a common inflammatory-thrombotic process that may occur spontaneously, after trauma or as a complication after medical or surgical interventions. In most of the cases it is a sterile inflammation of the vein wall and the surrounding tissue, accompanied by intravenous thrombosis (F 1).



F1: Thrombophlebitis of Great Saphenous Vein

In the rare cases of infectious superficial thrombophlebitis, the infection is introduced inside the veins, mostly after venous manipulations, by insects, traumatism or furunculosis (F 2).



F 2: Infectious thrombophlebitis

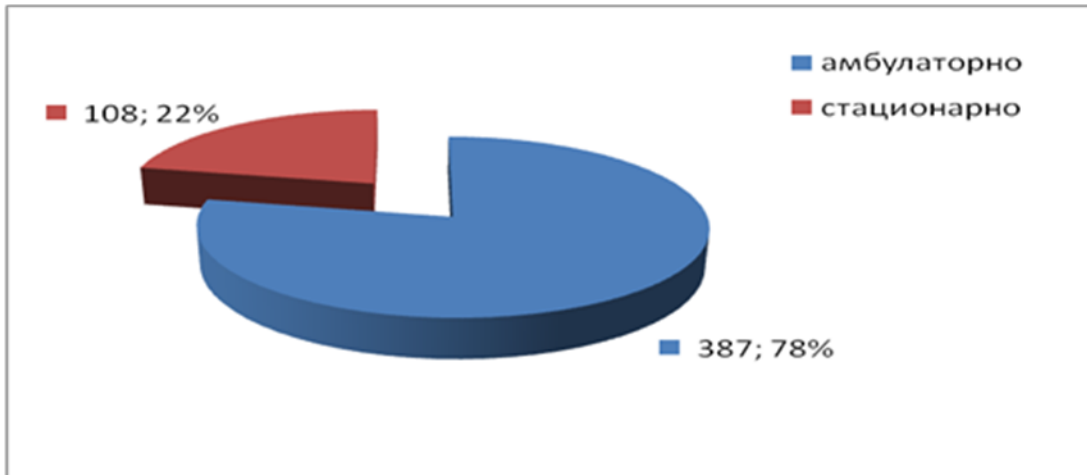
The goals of therapy for superficial thrombophlebitis are to prevent progression into the deep venous system and to

hasten the resolution of the inflammatory and thrombotic processes in areas already involved.

The nonsteroidal anti-inflammatory and venotonical drugs, low molecular weight heparin and nonsteroidal creams for local application are the first options. In the rear cases of infectious thrombophlebitis, the antibiotics are applied. When the thrombophlebitis of the saphenous veins reaches the saphenofemoral or saphenopopliteal junction, or cloth reaches the iliac veins, the surgical treatment is suggested.


MATERIALS AND METHODS

In a nine years period, since 01.01.2009 to 31.12.2017, 495 patients were treated by STP in Military medical Academy. They were divided in two groups. 108 (22%) patients from the first group, were admitted for surgery. The other group of 387 patients underwent conservative therapy. (F 3)



F 3: Number of patients (blue –conservative therapy; red-surgery)

The frequency of the disease is higher at women, probably because of pregnancy and the high rate of varicosis (5, 10, 12, 15). The superficial thrombophlebitis affects all the ages (from 18 to 87), but is most frequent between 50 and 60 years for men and women (5, 13, 14).(F 4)



F 4: Average ages of the patients (1-st column men, 2-nd column-women)

The conservative therapy is of the first choice in Superficial thrombophlebitis. It includes non steroid antiinflammatory drugs for local and parenteral / intra venous use, venotonics, and low weight heparin continued after ten days with antiagregant therapy. Antibiotics can be applied only in cases with infectious superficial thrombophlebitis. The patient is setted in motion. Standing straight or in bed slow up venous circulation and helps the cloth progression.

The conservative therapy has for an object to:

1. To stop the inflammation. The inflammatory process is the cause for pain and intravenous thrombosis.

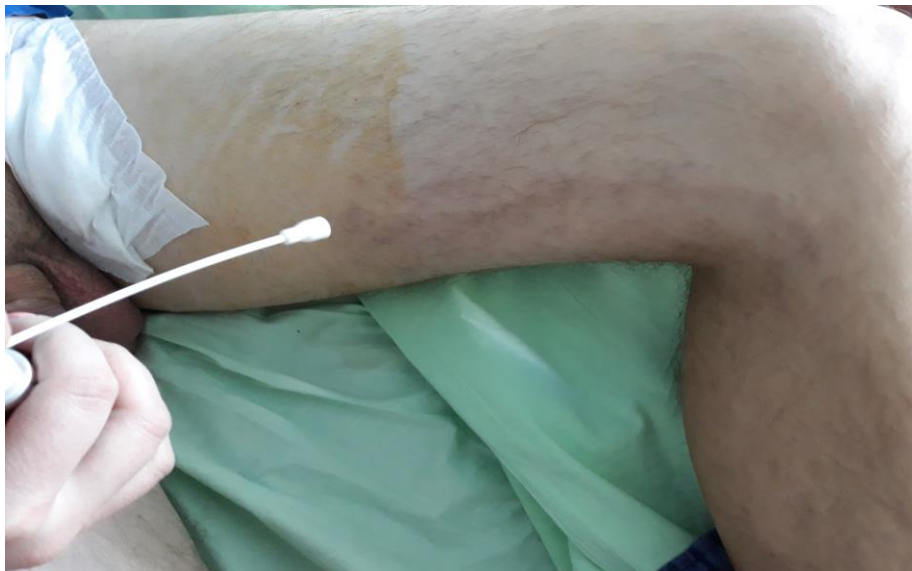The phlebitis and periphlebitis are responsible not only for the pain, but for sclerosis of surrounding tissue. That's why the ten days of antiinflammatory therapy for oral and local use is recommended.

2. To stop the clot progression into the deep veins. The risk of pulmonary thrombolism increase with the clot progression into the deep veins. The low weight Heparin stops the clot progression. After two week of anticoagulant therapy, it may be continued with antiagregant therapy

3. To stop the infection in that cases when an infection occurs. Antibiotics must applied, it is to be wished with the large spectrum antibiotics while waiting of an antibiogram results.

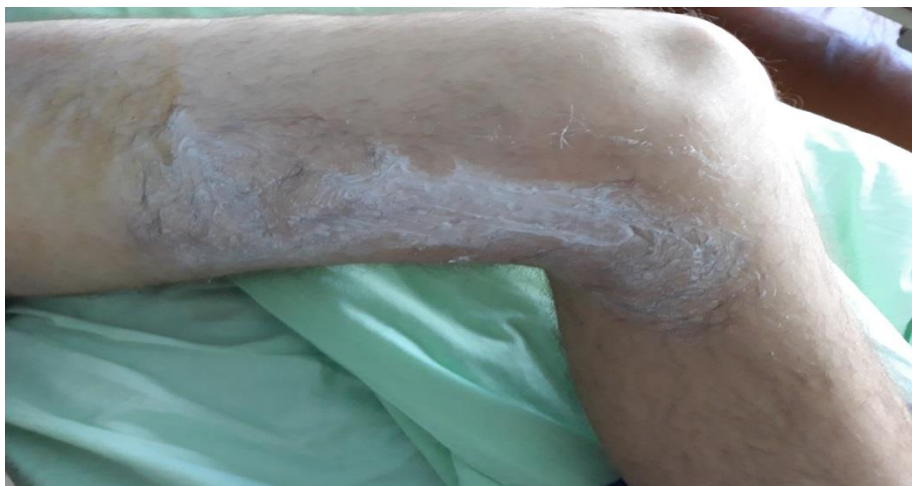Venotonics and elastic compression reduce the vein stasis and accelerate the venous blood flow.

In the last years we introduced a new method for local anesthesia. We use a 10% sol. Lidocaini over the affected superficial vein and the upper skin area. (F 5)



F 5: Local anesthesia with 10% sol. Lidocaini

Then corticosteroid ungv. is used to prolong the analgetic effect over the affected area (F 6) and to reduce the inflammation.



F 6: Local application of corticosteroid ungv.

CONCLUSIONS

1. The superficial thrombophlebitis is a serious disease, the underestimation of which some times has a fatal issue.
2. The frequency of the disease is higher at women, probably because of pregnancy and the high rate of varicosis.
3. The superficial thrombophlebitis affects all the ages (from 18 to 87), but is most frequent between 50 and 60 years for men and women.
4. The goals of therapy for superficial thrombophlebitis are to prevent progression into the deep venous system.
5. The nonsteroidal antiinflammatory and venotonical drugs, low molecular weight heparin and nonsteroidal creams for local application are the first options.
6. The patient needs to be under medical observation till come through an illness.
7. When the thrombosis reaches the sapheno –femoral or sapheno-popliteal junction, or the process invades the deep veins, the surgery is recommended.

BIBLIOGRAPHY

- [1] Андреев А. Съдови заболявания. Академично издателство „ проф. Марин Дринов”, София 1998; 174-176.
- [2] Андреев А., Първични варикозни вени и повърхностен тромбозит. В „Съдови заболявания , съдова и ендоваскуларна хирургия”, София, Знание, 2009, 145-155.
- [3] Й. Топалов, В. Анастасов, Ив. Зънзов. Постромбозитна болест. Медицина и физкултура. 1988 г. 20-21. 24.
- [4] Кириенко А., А. А. Матюшенко, В. В. Андрияшкин. Остри тромбозит. Издателство „Литерра”. 2006.
- [5] Цеков М. Хирургично лечение на повърхностния тромбозит: Дисертационен труд, София, 2018.
- [6] Andreev A. Vascular diseases and applied vascular surgery. Znanie 2007: 116
- [7] Ascer E, Lorenzen E, Pollina RM, Gennaro M. Preliminary results of a non-operative approach to sapheno femoral junction thrombophlebitis. J Vasc Surg 1995;22:616–621.
- [8] Beatty J, Fitridge R, Benveniste G, Greenstein D. Acute superficial venous thrombophlebitis: does emergency surgery has a role? Int Angiol 2002;21:93–95.
- [9] Chengelis DL, Bendick PJ, Glover JL, Brown WO, Ranval TJ. Progression of superficial venous thrombosis to deep veins. J Vasc Surg 1996;24:745–749.
- [10] Decousus H, Epinat M, Guillot K et al. Superficial vein thrombosis: risk factors, diagnosis and treatment. Curr Opin Pulm Med 2003;9:393–397.
- [11] DeWeese MS. Nonoperative treatment of acute superficial thrombophlebitis and deep femoral venous thrombosis. In: Ernst CB, Stanley JC, eds. Current therapy in vascular surgery. Philadelphia: BC Decker Inc. 1991; 952-960.)
- [12] Husni EA, Williams WA. Superficial thrombophlebitis of lower limbs. Surgery 1982;91:70–74.
- [13] Lohr JM, McDevitt DT, et al. Operative management of greater saphenous thrombophlebitis involving the saphenofemoral junction. Am J Surg 1992; 164: 269-275.
- [14] Lutter KS, Rerr TM, Roedersheimer R, Lohr JM, Sampson MG, Cranley JJ. Superficial thrombophlebitis diagnosed by duplex scanning. Surgery 1991;100:42–46.
- [15] Mayor M, Buron I et al. Mondor's disease. Int. J Dermatol 2000; 39:922-925
- [16] Unno N, Mitsuoka H, Uchiyama T et al. Superficial thrombophlebitis of the lower limbs with varicose veins. Surg Today 2002;32:397–401.

