
SURGICAL TREATMENT OF AORTIC REGURGITATION AND BILATERAL CORONARY ARTERY OSTIAL STENOSIS DUE TO CARDIOVASCULAR SYPHILIS

Zaprin Vazhev

Medical University – Plovdiv, Bulgaria, “St. George” University Hospital – Plovdiv, Bulgaria,
Department of Cardiovascular Surgery, vazhev@dir.bg

Asen Ivanov

Medical University – Plovdiv, Bulgaria, “St. George” University Hospital – Plovdiv, Bulgaria,
Department of Cardiovascular Surgery, acevanov1988@gmail.com

Todor Gonovski

Medical University – Plovdiv, Bulgaria, “St. George” University Hospital – Plovdiv, Bulgaria,
Department of Cardiovascular Surgery, tgonovski@yahoo.com

Hristo Stoev

Medical University – Plovdiv, Bulgaria, “St. George” University Hospital – Plovdiv, Bulgaria,
Department of Cardiovascular Surgery, hristostoev87@gmail.com

Abstract: We present the case of a 44-year-old gentleman, hospitalized in Interventional cardiology department with retrosternal pain. Percutaneous coronary investigation(PCI) was performed demonstrating bilateral ostial coronary artery stenosis with moderate aortic regurgitation. The patient was transferred in our department for urgent surgery. Cardiac surgery procedure was performed including: double coronary artery bypass grafting (CABG) combined with aortic valve replacement(AVR) with mechanical valve. The Venereal Disease Research Laboratory test (VDRL) and Treponema pallidum Haemagglutination(TPHA) test were done on admission – both of them being positive. Those results confirmed tertiary cardiovascular syphilis. The patient was discharged on POD 12, and was transferred to Dermatology and sexually transmitted diseases(STD) department for further antibiotic therapy concerning the syphilis infection.

Keywords: Cardiovascular syphilis, Aortic Valve Replacement, Coronary Artery Bypass Grafting.

INTRODUCTION

Syphilis is an ancient well known chronic systemic infection caused by Treponema pallidum. Nearly all cases are acquired by unprotected sexual contact. Despite the antibiotic therapy and protected intercourse which were expected to diminish that disease that wasn't achieved and we are still witnesses of the severe complications caused by that infection. Cardiovascular syphilis usually occurs 10–30 years after the initial infection and represents around 10% of all the tertiary forms[1]. We report a rare case of CABG combined with AVR in a patient with tertiary cardiovascular syphilis.

CASE PRESENTATION

We present a case of 44-year-old patient admitted in Interventional Cardiology Department with a clinical symptoms of rapidly progressing dyspnea and chest pain. The patient confirmed family history of cardiovascular disease. PCI(Figure 1) and aortography were conducted showing critical 95% ostial stenosis of the left main coronary artery(LMCA), 90% ostial stenosis of the right coronary artery(RCA) and 2nd degree moderate aortic insufficiency. The patient was transferred for an urgent cardiac operation. At admission 12-channel electrocardiogram(ECG) showed sinus rhythm with ST-segment depression in leads V2 to V6, as well as in II,III, AVF and AVL leads. The trans-thoracic echocardiography performed preoperatively demonstrated left ventricle ejection fraction of 48%. The measured diameter of aortic root was 24mm, aortic bulbus: 39mm, ascending aorta: 38mm. Aortic valve was with mean gradient of 8mmHg and moderate 2nd degree aortic regurgitation. Left ventricle: interventricular septum – 10mm, posterior wall thickness – 10mm, Telediastolic diameter(TDD) – 66mm, Telesystolic diameter(TSD) – 49mm, Telediastolic volume – 162ml, Telesystolic volume – 87ml. Mitral valve – 1st degree regurgitation. Tricuspid valve – 1st degree regurgitation. The calculated EuroSCORE II(European System for Cardiac Operative Risk Evaluation) of the patient was 7.72%

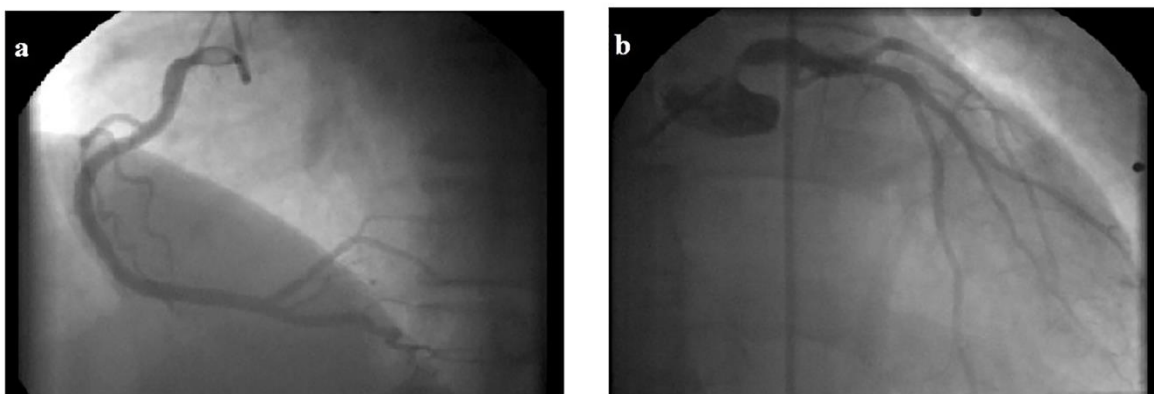


Figure1- Preoperative PCI: a- 90% stenosis of the RCA; b- 95 critical ostial stenosis of the LMCA; Normal distal coronary bed.

The patient was urgently operated including double CABG: left anterior descending artery(LAD)-left internal thoracic artery(LIMA), RCA-right internal thoracic artery(RITA) and AVR with mechanical valve. After full median sternotomy, cardiopulmonary bypass(CPB) was established, venting was inserted in the left ventricle trough the right superior pulmonary vein(RSPV). At mild hypothermia, the arrest was achieved by cold blood cardioplegia solution administered in a retrograde and antegrade fashion. Aortic valve cusps were excised and 23-mm Sorin Carbomedics (SorinGroup, Saluggia, Italy) mechanical aortic valve was implanted. The distal anastomoses on the RCA and LAD were completed with arterial (RITA and LITA) conduits. After the completion of the distal anastomoses and closing of the aorta via continuous 4/0 polypropylene suture the extracorporeal circulation was terminated with optimal dopamine dose support. The total CPB time was 127min. and aortic cross-clamp time was 87min.

The perioperative antibiotic treatment with Cefuroxime 2g/dialy was initiated. The postoperative period was uneventful. The patient was extubated on the POD 1, the mediastinal chest tubes removed on the POD 2 and estimated total blood loss 320ml. There wasn't any other major cardiovascular events(MACCE). After the laboratory results of the Venereal Disease Research Laboratory(VDRL) and Treponema pallidum Haemagglutination(TPHA) test and after consultation with STD consultant the treatment was changed to dual antimicrobial therapy with Penicillin G 7.2 million Units total, administered in 3 doses of 2.4 million each on 1-week intervals and Ceftriaxone 2x1g/day for 7 days. The patient was discharged on the POD 12 and was referred to Dermatology and STD Department for further antibiotic therapy regarding the syphilis infection. Control VDRL and TPHA tests remained negative at 6th month and 1st year follow-up. Follow-up computed tomography(CT) scan at 6th month(Figure 1) and 1 year(Figure 2) detected no progression in the diameter of the aorta.

Figure 2a: CT-scan performed six months after discharge demonstrating no progression in the diameter of the aorta.

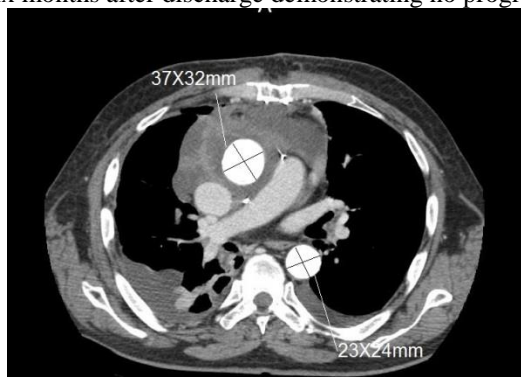


Figure 2b: CT-scan performed one year after discharge demonstrating no progression in the diameter of the aorta.

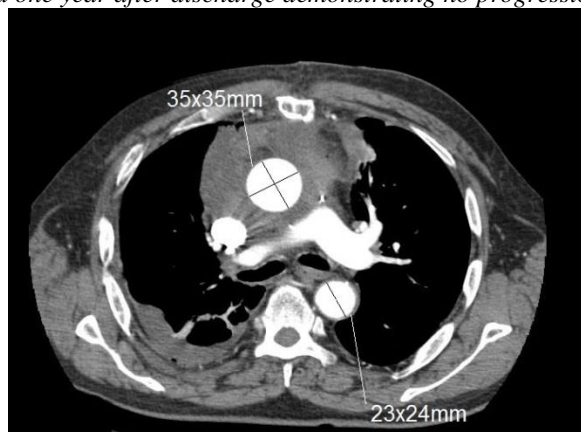
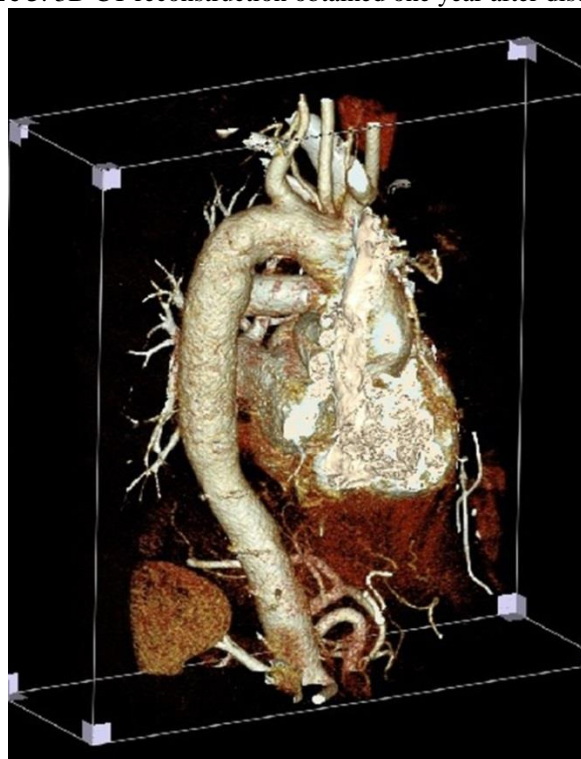


Figure 3: 3D CT reconstruction obtained one year after discharge.



DISCUSSION

The cardiovascular complications of tertiary syphilis predominantly involve the aorta, leading to the formation of aneurysms and aortic valve incompetence. Angina may result from coronary syphilitic ostial stenosis or associated atherosclerosis[2]. Normal coronary bed distally favours syphilitic genesis than atherosclerotic one as it was in our case. The list of differential diagnosis with conditions causing similar pathology are Marfan syndrome, Kawazaki disease, Takayasu arteriitis, Systemic Lupus Erythematosus(SLE)[3].

The decision of performing total arterial revascularization using bilateral internal thoracic arteries(BITA) was taken because of the medical state of our patient: the young age, absence of diabetes, obesity and last but not least – the numerous reports favouring arterial over venous graft application in CABG. Regarding the decision of AVR with mechanical valve: in middle-aged patients bioprosthetic valves may have a higher rate of major complications compared to mechanical valves during long-term follow-up[4].

The guidelines of the European Society of Cardiology(ESC/EACTS/) on the diagnosis and treatment of aortic disease

recommend operative repair of the aortic root and the ascending aorta at the class IIa level when there is an evident aortic root aneurism and the diameter of the ascending aorta is equal to or greater than 45mm[5]. In our case that was not performed because the diameter of the aortic root and ascending aorta were 24- and 38mm respectively, measured in pre- and intraoperative findings. If the findings are following the guidelines criteria, aortic root/ascending aorta replacement is strongly recommended.

Syphilis infection seems to be not so rare and impossible diagnosis in today's modern world, even in the developed countries. This case is a reminder that we should not exclude cardiovascular syphilis as a cause of bilateral coronary artery ostial stenosis combined with aortic regurgitation especially among young patients.

CONFLICT OF INTEREST

None declared.

REFERENCES

- [1] Kent ME, Romanelli F. *Reexamining syphilis: an update on epidemiology, clinical manifestations, and management.* *Ann Pharmacother.* 2008 ;42 (2): 226–36. doi:10.1345/aph.1K086
- [2] Peter J. Pugh, M.B., B.S., Ever D. Grech, M.D. Syphilitic Aortitis. *N Engl J Med.* 2002 ; 346:676. doi:10.1056/NEJMicm010343
- [3] Maclead CB, Johnson D, Frable WJ. “Tree barking” of the ascending aorta. *Am J Clin Pathol.* 1992 ;97:58-62.
- [4] Kulik A, Bedard P, Lam BK, Rubens FD, Henry PJ, Masters RJ, et al. Mechanical vs bioprosthetic valve replacement in middle-aged patients. *Eur J Cardiothorac Surg.* 2006 ;30 (3): 485-491. doi:10.1016/j.ejcts.2006.06.013
- [5] Zamorano JL, Achenbach S, Baumgartner H, Bax JJ, Bueno H, Dean V, et al. 2014 ESC Guidelines on the diagnosis and treatment of aortic diseases. *Eur Heart J.* 2014; 35:2873-2926. doi:10.1093/eurheartj/ehu281