
SURGICAL TREATMENT OF AORTIC COARCTATION IN 29-YEAR OLD PATIENT

Zaprin Vazhev

Medical University – Plovdiv, Bulgaria, “St. George” University Hospital – Plovdiv, Bulgaria,
Department of Cardiovascular Surgery, vazhev@dir.bg

Asen Ivanov

Medical University – Plovdiv, Bulgaria, “St. George” University Hospital – Plovdiv, Bulgaria,
Department of Cardiovascular Surgery, acevanov1988@gmail.com

Todor Gonovski

Medical University – Plovdiv, Bulgaria, “St. George” University Hospital – Plovdiv, Bulgaria,
Department of Cardiovascular Surgery, tgonovski@yahoo.com

Hristo Stoev

Medical University – Plovdiv, Bulgaria, “St. George” University Hospital – Plovdiv, Bulgaria,
Department of Cardiovascular Surgery, hristostoev87@gmail.com

Abstract: We present a case of 29-year-old-woman diagnosed with severe coarctation of the aorta 15mm distal to the left subclavian artery. The patient was admitted in our institution, computed tomography(CT) scan was performed - confirming the diagnosis. After heart team meeting discussion, decision was taken for surgical correction as the best option for the case. Cardiac surgery procedure was performed including: resection of coarctation segment and aortic prosthesis interposition using left heart bypass for optimum spinal cord and visceral organs protection. The patient was discharged on postoperative day 7 on drug therapy with antiplatelet and dual antihypertensive therapy with β -blocker and calcium channel blocker: Aspirine, Metoprolol and Lercanidipine. At late follow-up examination one year after the surgical correction the patient was normotensive at rest, as well as after treadmill stress test using the standart Bruce protocol. Despite the established good cardiac prophylaxis on newborns, sometimes this disease can remain undiagnosed until adulthood when the complications are starting to present.

Keywords: aortic coarctation; surgical repair; left heart bypass.

CASE PRESENTATION

We present a case of 29-year-old lady diagnosed with unresponsive to drug therapy arterial hypertension. At admission the clinical examination showed normal body habitus. The skin and the visible mucous membranes were with normal coloration. Lungs – bilateral vesicular breathing on auscultation. Visible chest wall collateral pulsations. Cardio-vascular system – heart frequency rate of 77 bpm, rhythmic heart activity, arterial blood pressure of 180/80 mmHg, clear heart sounds, rough systolic murmur audible in the 3th intercostal space in the paravertebral area bilaterally. Abdomen – on the chest level, soft abdominal wall without palpatory tenderness. Liver – palpated on 3 cm above the right costal margin, and the spleen was not enlarged on palpation. Succusio renalis – bilaterally negative. Arterial pulsations on upper extremities were normally palpable. Femoral, popliteal, tibial and dorsal ones were barely perceptible.

The 12-channel electrocardiogram(ECG) showed sinus rhythm with normal QRS axis. The trans-thoracic echocardiography demonstrated left ventricle ejection fraction of 75%. Left ventricle: interventricular septum – 10mm, posterior wall thickness – 13mm, Telediastolic diameter(TDD) – 45mm, Telesystolic diameter(TSD) – 25mm, Telediastolic volume – 91ml, Telesystolic volume – 23ml. Aortic valve: with three cusps, mean gradient of 8mmHg and absence of aortic regurgitation. Mitral and tricuspid valve – without deviations. Measured diameter of aortic root was 22mm, aortic bulbus: 36mm, ascending aorta: 30mm, aortic arch: 29mm. Visible obstruction of the descending aorta just distal to the left subclavian artery with measured peak systolic gradient of 76mmHg. The chest X-ray(Figure 1) showed normal cardiothoracic index and visible inferior rib notching. CT scan(Figure 2) was performed for determination of the exact location of the coarctation segment showing severe coarctation of descendent thoracic aorta 15mm distal to the left subclavian artery. Laboratory test results were within the normal ranges.

The patient was discussed at heart team meeting and decision was taken for surgical treatment as the best option for the case. The calculated EuroSCORE II (European System for Cardiac Operative Risk Evaluation) of the patient was 11.56%.

Figure 1 : Pre-operative chest X-ray with apparent inferior rib notching.

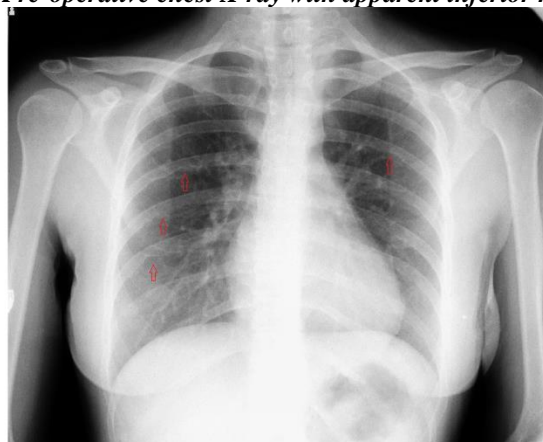
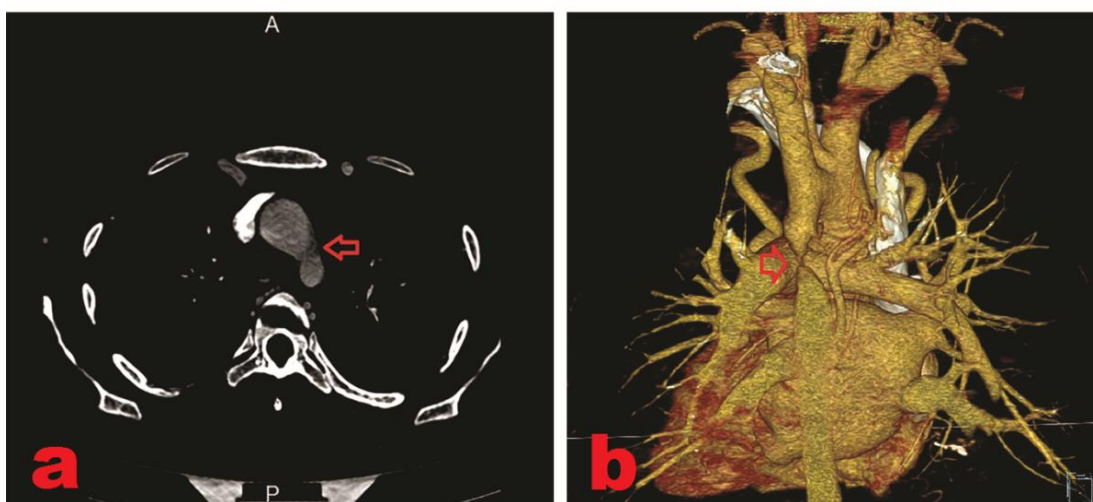
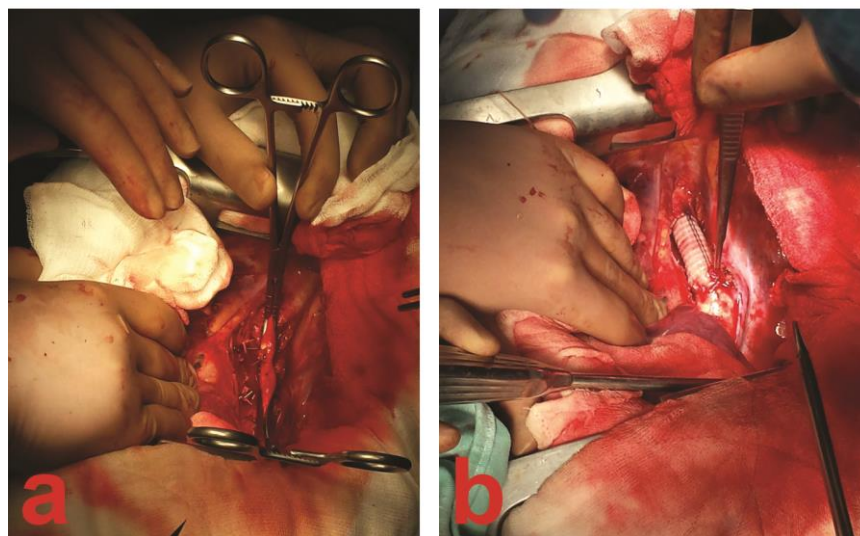


Figure 2 : Pre-operative: CT-scan(a) with Reconstruction(b), confirming the diagnosis.



The cardiac surgery procedure (Figure 3) was performed via left lateral thoracotomy in 4th costal interspace, including: Resection of the aortic ductal tissue and 14-mm Polymale aortic prosthesis interpositioning (Perouse Medical, Ivry-Le-Temple, France). For optimum spinal cord and visceral organs protection left heart bypass (LHB): left superior pulmonary vein to the left femoral artery after full heparinisation on normothermy was used. Arterial blood pressure was constantly monitored proximal and distal to the aortic clamps on radial and femoral artery respectively. After the completion of the distal anastomosis, the LHB was terminated without catecholamine support. The total LHB time was 38min.

Figure 3 : Intraoperative: a- segment resection; b- prosthesis interposition.

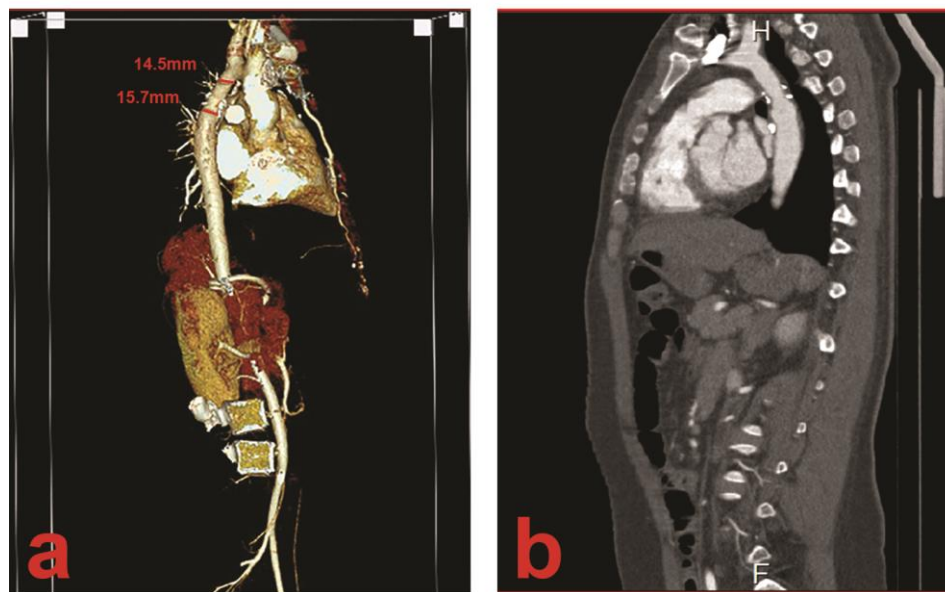


In the postoperative period the patient was extubated on the 3th postoperative hour. The mediastinal chest drains were removed on the 2nd postoperative day, and the estimated total blood loss was 160ml. Chest pulsations which were visible preoperatively disappeared, and femoral, popliteal, tibial and dorsal pulsations became palpable as the ones in the upper limbs.

The patient was discharged on the 7th postoperative day, on medical therapy with Metoprolol 50mg and Lercanidipine 10mg twice daily, antiplatelet therapy - Aspirine 100mg daily for 3 months and recommendations were given for follow-up examinations each year as well as control CT-scans in 5-year intervals.

At late follow-up visit one year after the correction the patient was normotensive at rest and after treadmill stress test using the standart Bruce protocol. Control CT-scan was performed(Figure 4) showing normally functioning descending aorta prosthesis.

Figure 4 : CT-scan performed one year after the surgical correction. a- Reconstruction, showing 14.5mm proximal and 15.7mm distal anastomosis diameter; b- Sagittal scan;



DISCUSSION

The aortic coarctation represents 5-8% of all babies born with congenital heart defect (CHD) and may lead to premature death if remain uncorrected^[1]. It is one of the most commonly delayed diagnoses, not to mention that about 30% of all patients with CHD are discharged from the birth hospitalization undiagnosed^[2]. Our case is the same. The patient's first and only symptom was unresponsive to drug treatment arterial hypertension, which occurred at the late third decade of her life.

Early diagnosis and repair are essential for permanent elimination of the arterial hypertension and leaving no residual one, along with all the other devastating complications which occur in the older age like: cerebrovascular incidents, aortic aneurysms, aortic dissection, heart failure etc.

In recent years many studies are considering transcatheter interventions to be an alternative to surgery in treating cardiac diseases. Aortic coarctation is not an exception. Nonetheless, the higher incidence of periprocedural complications(aortic aneurysm formation, stent migration, bleeding etc.) compared to surgical repair still make surgery to be considered as a better option for treating aortic coarctation. In patients with re-coarctation, concomitant cardiac diseases, comorbidities increasing the risk of surgery etc., endovascular stenting can be considered as acceptable alternative to surgery^[3,4].

In our practice, we routinely use LHB because of its proven superior results in many studies regarding spinal cord and visceral organs protection during the surgical treatment of thoracic and thoracoabdominal aorta, and low incidence of paraplegia - which is one of the most fearsome surgical complications^[5,6,7,8].

The dispute regarding which surgical technique is the best for the repair of the aortic coarctation, has not yet been concluded. Many studies showed that this depends on many factors as: age, presence of hypoplastic aortic arch, previous operation, severe aortic wall calcification etc. In our opinion resection with extended end-to-end anastomosis technique still remains the gold standard for pediatric patients undergoing surgical treatment because of its lowest rate of re-operation as a result of re-coarctation. Whenever is possible to be applied(adequate aortic mobility, short coarctation segment) - it is the technique of choice in adult patients also. Resection with graft interpositioning is the best alternative to extended end-to-end anastomosis especially in adult patients with long-segment coarctation. This technique provides durable long-term results and excellent long term survival^[9]. The technique of patch aortoplasty has never been used in our institution due to high incidence of aortic aneurysm formation reported by many authors^[10,11]. Subclavian flap aortoplasty technique is reserved mainly in pediatric patients. Long-term arm length divergence and claudication with exercise due to compromised arterial supply are the biggest disadvantage of this technique. Severe left arm ischemia is rare complication^[12]. Extra-anatomic aortic bypass technique is considered in patients with severe aortic arch hypoplasia, long coarctation, re-coarctation, redo-operations as well as in cases with heavy aortic wall calcification^[13].

ACKNOWLEDGEMENTS

Disclosure: The authors declare no conflict of interest.

REFERENCES

- [1] Keith JD, Rowe RD, Vlad P. Heart Disease in Infancy and Childhood. 1978; New York, NY, Macmillan 3: 4-6.
- [2] Hoffman JI. It is time for routine neonatal screening by pulse oximetry. Neonatology 2011; 99:1
- [3] Magee AG, Brzezinska-Rajszyz G, Qureshi SA, Rosenthal E, Zubrzycka M, Ksiazek J, Tynan M. Stent implantation for aortic coarctation and recoarctation. Heart 1999; 82:5 600-606. doi:10.1136/hrt.82.5.600
- [4] Harrison DA, McLaughlin PR, Lazzam C, Connely M, Benson LN. Endovascular stents in the management of coarctation of the aorta in the adolescent and adult: one year follow up. Heart 2001;85:561-566. doi:10.1136/heart.85.5.561
- [5] Westaby S, Parnell B, Pridie RB. Coarctation of the aorta in adults. Clinical presentation and results of surgery. J Cardiovasc Surg (Torino) 1987; 28(2): 124-127.
- [6] Szwerc MF, Benckart DH, Lin JC, et al. Recent Clinical Experience With Left Heart Bypass Using a Centrifugal Pump for Repair of Traumatic Aortic Transection. Annals of Surgery. 1999; 230(4): 484.
- [7] Wong CH, Watson B, Smith J, Hamilton JR, Hasan A. The use of left heart bypass in adult and recurrent coarctation repair. Eur J Cardiothorac Surg. 2001;20(6):1199-201.
- [8] Ferreira EC, Nina VJS, Assef MAS, da Silva NAC, Gaspar SFD, da Silva FACC, Nascimento RS. Surgical repair of coarctation of aorta in adults under left heart bypass. Brazilian Journal of Cardiovascular Surgery. 2012; 27(1), 97-102. doi:org/10.5935/1678-9741.20120014

- [9] Yousif A, Kloppenburg G, Morshuis WJ, Hijmen R. Repair of adult aortic coarctation by resection and interposition grafting. *Interact CardioVasc Thorac Surg* 2016; 23(4): 526-530. doi: 10.1093/icvts/ivw206
- [10] Campbell M. Natural history of coarctation of the aorta. *Br Heart J* 1970; 32: 633-40.
- [11] Celermajer DS, Greaves K. Survivors of coarctation repair: fixed but not cured. *Heart*. 2002; 88: 113–114. doi: 10.1136/heart.88.2.113.
- [12] Vergales JE, Gangemi JJ, Rhueban KS, Lim DS. Coarctation of the aorta - the current state of surgical and transcatheter therapies. *Curr Cardiol Rev*. 2013; 9: 211–219.
- [13] Berdat PA, [Göber](#) V, Carrel T. Extra-anatomic aortic bypass for complex (re-) coarctation and hypoplastic aortic arch in adolescents and adults. *Interact CardioVasc Thorac Surg* 2003; 2(2): 133-137. doi: 10.1016/S1569-9293(02)00122-6.

