
ANATOMICAL VARIATIONS OF MENTAL FORAMEN IN ADULT HUMAN MANDIBULES

Svetlana Jovevska

University “Goce Delcev” Stip Republic of Macedonia; svetlana.jovevska@ugd.edu.mk

Elizabeta Zisovska

University Clinic for Gynecology and Obstetrics, Skopje, Republic of Macedonia, and University “Goce Delcev” Stip; elizabeta.zisovska@ugd.edu.mk

Lence Nikolovska

University “Goce Delcev” Stip Republic of Macedonia; lence.nikolovska@ugd.edu.mk

Abstract: Background: The principal complication of surgery of the mental foramen region is paralysis of the mental nerve. Identification of mental foramen is thus important to dental surgeons in nerve blocks and in doing surgical procedures like apicocurettage of mandibular premolars, amalgam filling, periodontal surgery etc. so as to avoid injury to neurovascular bundle. Accessory mental foramina tend to exist in the apical area of the first molar and posterior or inferior area of the mental foramen. Verification of the existence of accessory mental foramina would prevent accessory nerve injury during periapical surgery. In root canal treatment, the possibility of accessory mental foramina-related nerve paraesthesia seems low unless the mental foramen is injured. These foramina have been found to vary in position in different ethnic groups. Therefore, knowledge of morphology of mental foramen will enable effective mental block anaesthesia.

Aim: To determine the morphological features of mental foramen in population to provide guidelines for forensic scientists and dentists.

Materials and Methods: 100 adult male and female human mandibles were obtained. Size, incidence, shape, location and number of mental foramina were recorded. Incidence of accessory mental foramina was also noticed. Distance from anatomical landmarks and size was recorded using vernier caliper

Results: Mental foramen was present in all hundred observed mandibles and it was bilateral. 1.5% of the mandibles showed double mental foramen which was present in the right side. None of the mandibles presented with bilateral accessory mental foramen. Taking both sides into consideration, round shaped mental foramen were observed in 106 mandibles and oval shaped in 94 mandibles. The most common position was on the longitudinal axis of the second premolar.

Conclusions: The morphologic variations of mental foramen are clinically important for dental surgeons and anaesthetists.

Keywords: Mental Foramen, Morphology, Apicocurettage of Mandibular Premolar, Position of Mental Foramen

INTRODUCTION

The mental foramen is an opening located on the external surface of the mandible in the region of the mandibular premolars. Mental nerve and vessels pass through mental foramen.

Normally, mental foramen is located below the interval between the premolars. However, variations in the location of the foramen have been reported. It may lie between the apices of lower premolars or below the apex of second premolar [1]. In apicocurettage of mandibular premolars, the dentist depends on the relation of the mental foramen to the lower premolar and to the body of ramus; otherwise operation on the lower premolar may damage the mental nerve. The mental nerve injury can cause transitory or permanent sensitive, thermal and tactile changes in the areas of its innervations [2]. Knowledge of the most common position of the mental foramen of a local population is very important for oral surgeon both when administering regional anesthesia and performing periapical surgery in the mandible like implantation operations. Although it is often possible to identify the mental foramen by palpation and radiographically, knowing the normal range of possible location is essential [2]. The presence of small foramina identified as accessory mental foramina in the surrounding area of the mental foramen has also been discovered [3, 4]. The reported frequency of occurrence of accessory mental foramina has varied between less than 5% and about 30% [5-7]. Toh et al. [8] described the distributions of accessory mental nerve emerging from the accessory mental foramina to the mucous membrane and skin of the corner of mouth to the labial region. The group indicated the possible occurrence of pain caused by injury of the nerves emerging from the accessory mental foramina by an injection via the mucous membrane. Boronat López et al. [9] mentioned the accessory mental foramina as one of the

factors implicated in regional anesthesia failure. So, the present study was undertaken to provide information on number, shape, position and variations of mental foramen. The results of this study will furnish a reference for dentists in clinical practices. Aim: To study the morphological characteristics and variations of mental foramen in the dry adult human mandible

MATERIALS AND METHODS

The study included 100 dry human mandibles of undetermined age and gender (as they were not recorded at the time of acquisition) procured from the Department of Anatomy

Each mandible was assigned a serial number. The results obtained were recorded and tabulated. The different parameters recorded were: 1. The number of mental foramina (Fig. 1 and Fig. 2) 2. The shape of mental foramina whether oval (Fig. 3) or round (Fig. 4) 3. The position of mental foramen in relation to the roots of mandibular teeth (Fig. 5) The position of the mental foramen was recorded as either in line with the longitudinal axis of the tooth or lying in between two teeth according to following scheme: If any part of the foramen lay on a line drawn perpendicular to the occlusal plane passing along the longitudinal axis of a tooth, the foramen was assigned that position. If any part lay on a similar line passing through the contact area between the teeth, it was assigned that position. If the foramen was too small to intersect a line or too large, intersecting two lines, then it was assigned more anterior position. against the lateral aspect of the mandible.



Fig. 1: Single mental foramen

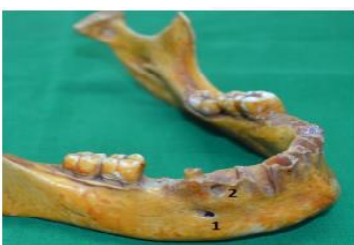

Fig. 2: Double mental foramen.

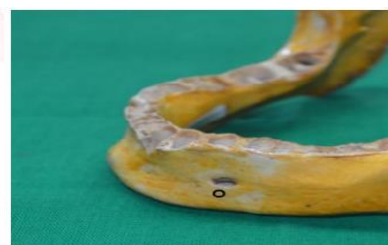

Fig 3: Oval shape mental foramen.

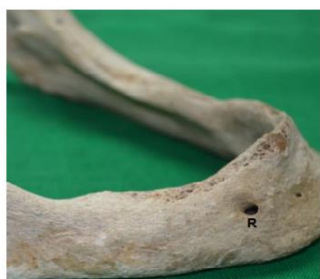

Fig. 4: Round shape mental foramen

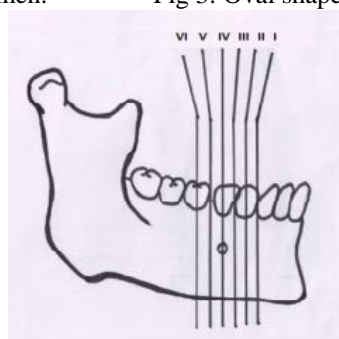


Fig. 5: Illustration showing position of mental foramen in relation to the mandibular teeth (schematic diagram)

RESULTS

Incidences of Mental Foramen: Mental foramen was present in all one hundred observed mandibles and it was bilateral. Incidences of Accessory Mental Foramen: 1.5 % of the mandibles showed double mental foramen which was present in the right side (Fig. 2). Out of these, there was a single large

foramen while the others were small (satellite) foramina. There was no triple mental foramen. None of the mandibles presented with bilateral accessory mental foramen. Round shaped mental foramen were observed in 106 sides of the mandibles and oval shaped in 94 sides of the mandibles (Fig. 6)

Mental foramen was situated below the apex of second premolar tooth in 46.5 % mandibles (position IV) whereas in 27.5 % it was found between second premolar and first molar (position V). In 11 % of mandibles it was observed between first and second premolars (position III). It was seen below the apex of first premolar (position II) and below first molar (position VI) equally (2 % each). The mental foramen was not observed in between canine and first premolar (position I) in any mandible. In 22 sides, position could not be determined as they were edentulous.

Position of accessory mental foramen (in 1 mandible out of 100) was found to be situated 13 mm lateral from the mental foramen below apex of first molar tooth (position VI) (Fig. 7)

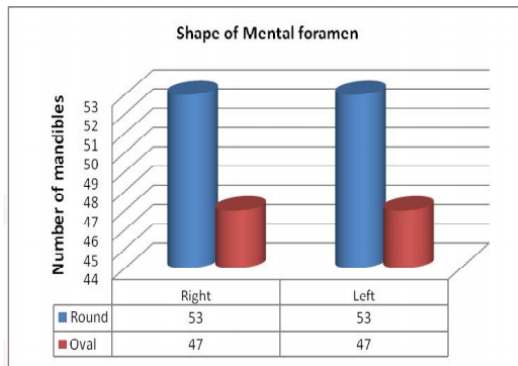


Fig. 6: Shape of mental foramen.

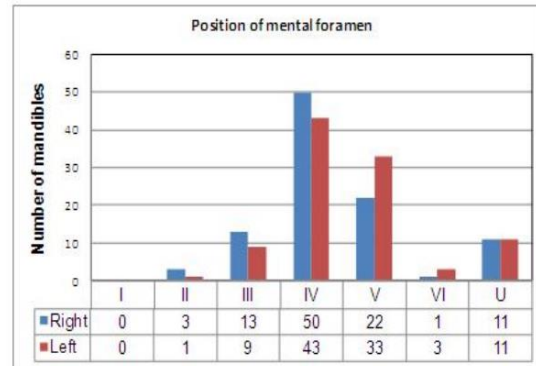


Fig. 7: Position of mental foramen.

DISCUSSION

The knowledge of the various parameters of mental foramen is important as it helps to avoid damage to the mental nerve in surgical procedures, aids in interpreting anatomical landmarks in oral pathology and important for implant techniques. Understanding the position of these foramina will also assist the clinician in performing local anaesthetic blocks. This information may play an even more important role in recently developed minimally invasive surgery techniques. Hence, the present study measured various dimensions of mental foramen. Number of mental foramina: Table 1 shows that the number of mental foramen found in the present study resembled with the findings of Stithipom. Azaz & Lustmann (1973) reported multiple mental foramina in 8.6 % of the sides [14]. Jaffar et al. reported multiple mental foramina in 30 % of the mandibles on either side. Only 4 % of the mandibles showed bilateral multiple mental foramina [13]. Gershenson et al. (1986) reported multiple foramina in 5.1 % of the mandibles [5].

CONCLUSION

In conclusion, the present analysis revealed variations in number, shape and position of mental foramen and accessory mental foramen. The present study suggests that local differences in mental foramen position may occur in a population. These may be related to feeding habits of different regions which may ultimately affect the development of mandibles. This variability should alert the dental surgeons while performing periodontal or endodontic surgery. The mental foramen is difficult to localize as there are no absolute anatomical landmarks for reference. The mental foramen cannot be visualized or palpated clinically; hence it is localized in relation to the lower teeth. Further, when the existence of the accessory mental foramen is confirmed, it could avoid nerve injury during periapical surgery. The possibility of accessory mental foramen related sensory disturbance is low during root canal treatment unless the mental foramen and mandibular canal are injured. If the studies related to variations in the

position, size, incidence and shape of mental foramen and accessory mental foramen are carried out in large numbers; it will be of immense use to the anthropologists in identifying the deceased. Moreover, the data will be reliable for dental surgeons

REFERENCES

- [1]. Collins P. Infratemporal and Pterygopalatine Fossae and Temporomandibular Joint. Standring S, editor. Gray's Anatomy: the Anatomical Basis of Clinical Practice. 40th edition. New York: Elsevier Churchill Livingstone; 2008: 527-560.
- [2]. Sankar DK, Bhanu SP, Susan PJ. Morphometrical and morphological study of mental foramen in dry dentulous mandibles of South Andhra population of India. Indian J Dent Res 2011;22:542-546.
- [3]. Riesenfeld A. Multiple infraorbital, ethmoidal, and mental foramina in the races of man. Am J Phys Anthropol. 1956;14:85-100.
- [4]. Sutton RN. The practical significance of mandibular accessory foramina. Aust Dent J. 1974;19:167-173.

- [5]. Gershenson A, Nathan H, Luchansky E. Mental Foramen and Mental Nerve: Changes with Age. *Acta Anat (Basel)*. 1986;126(1):21-28.
- [6]. Sawyer DR, Kiely ML, Pyle MA. The Frequency of Accessory Mental Foramina in Four Ethnic Groups. *Arch Oral Biol*. 1998 May; 43(5):417-420.
- [7]. Agthong S, Huanmanop T, Chentanez V. Anatomical Variations of the Supraorbital, Infraorbital, and Mental Foramina Related to Gender and Side. *J Oral Maxillofac Surg*. 2005 Jun;63(6):800-804.
- [8]. Toh H, Kodama J, Yanagisako M, Ohmori T. Anatomical Study of the Accessory Mental Foramen and the Distribution of its Nerves. *Okajimas Folia Anat Jpn*. 1992;69:85-87.
- [9]. Boronat López A, Peñarrocha Diago M. Failure of locoregional anesthesia in dental practice: review of the literature. *Med Oral Patol Oral Cir Bucal*. 2006;11:E510-513.