
VARIATIONS OF HUMAN RENAL ARTERY

Jovevska Svetlana

Faculty of Medical Sciences, GoceDelcev, University, Stip, Republic of Macedonia,
svetlana.jovevska@ugd.edu.mk

Zisovska Elizabeta

Faculty of Medical Sciences, GoceDelcev, University, Stip, Republic of Macedonia,
elizabeta.zisovska@ugd.edu.mk

Nikolovska Lence

Faculty of Medical Sciences, GoceDelcev, University, Stip, Republic of Macedonia
lence.nikolovska@ugd.edu.mk

Abstract: The aim of the study was to determine the distribution patterns of multiple renal arteries, evaluate how they are affected by gender and bilateral asymmetry and proceed on a systematic review. One hundred and six kidneys from 53 cadavers (27 males and 26 females) were investigated. The number and pattern of multiple renal arteries were determined according to side, gender and level of origin. The distances between the main renal and first multiple renal arteries were also measured. Multiple renal arteries were present in 5.6% of the kidneys. No statistically significant difference was found between side and gender ($p > 0.05$). The incidence of multiple renal arteries was 43% unilaterally and 6% bilaterally. As regards the multiple renal arteries, a single artery was detected in 43%, two in 6% and three in 2.3% in 15.5% (3/12) of the kidneys, there was a short common trunk (<1.5 cm), early dividing into the main renal artery and a thinner artery. Multiple renal arteries on the left side seemed to emerge lower than the right ones and displayed a greater variability at their origin. In the systematic review, we detected the patterns of multiple renal arteries which were classified according to population, gender, side and specimen (cadaveric, radiological or transplant). The awareness of morphology and topography of the multiple renal arteries is important in order to achieve a safe pre and intraoperative management of the renal vascular supply.

Keywords: kidney, renal artery, origin, variation, gender.

INTRODUCTION

Kidney arteries represent the 5th branch of the abdominal aorta, and arise from the lateral part of this artery, between the upper edge of the L1 and the lower edge of L2.

The arterial supply of the kidneys is quite variable. Except the main renal artery (RA), the presence of one or more additional RAs unilaterally or bilaterally is the commonest arterial anatomical variation of the kidneys [1]. Several terms have been used for multiple renal arteries (MRA) [2–5], such as “accessory” [1, 6–15], mentioned that the term “aberrant” should be used for arteries originating from other vessels than abdominal aorta (AA), even though urologists use this term for the vessels that compress the pelvis or ureter. The incidence of MRA presents a wide variability with a range from 8.7 to 75.7% (median 28.2%). The MRA are commonly detected unilaterally (30%) than bilaterally (10%) [1,] and their incidence presents racial diversity. Although individuals with multiple vessels are normal, the MRA presence may potentially complicate the transplant surgery, RA embolization or angioplasty, the reconstructive management of AA aneurysms and urological interventions. In addition, the higher MRA frequency is related to the risk of renovascular hypertension, hydronephrosis, ureteropelvic junction obstruction and chronic pyelonephritis. Gupta and Tello (2004) mentioned that accessory RAs in 24% of the hypertensive patients represent a vascular anomaly and not a direct cause of hypertension. The objective of this study is to detect the incidence of this abnormality, assess the morphological and topographical layouts in, and evaluate how these parameters are affected by gender and bilateral asymmetry. Moreover, a systematic review has been made in order to provide a comprehensive aspect of the topic.

MATERIALS AND METHODS

One hundred and six kidneys from 53 cadavers (27 males and 26 females) aging between 39–98 years were investigated. The number and pattern of multiple renal arteries were determined according to side, gender and level of origin. In some cases kidneys and related structures were excised en-bloc for a better visualization of the exposed area. Following the standard method of dissection, the abdominal cavity was opened and organs and retroperitoneum were removed in order to obtain a better access of the kidneys and their vessels. All measurements were calculated using a Vernier digital caliper (accuracy, 0.01 mm), and the center of the origin of each artery was taken as recordable point. The incidence of each variable was recorded and descriptive statistics (mean, median, minimum, maximum and standard deviation) were evaluated for the continuous variables. In order to compare the variables, chi-square test and Student’s t-test were applied.

RESULTS

The MRA were detected in 11.2% (23/206) of the kidneys. In 52.2% (12/23), MRA were found on the right and in 47.8% (11/23) on the left side. In males, MRA were detected in 11.3% (12/106), 50% (6/12) on the left and 50% (6/12) on the right side. In females, MRA were present in 11% (11/100), 54.5% (6/11) on the right and 45.5% (5/11) on the left side (Table 1). No statistically significant difference was found between gender and side ($p>0.05$).

Table 1 – The incidence of multiple renal arteries (MRA) according to gender and side

[36] Gender	[37] Presence of MRA				[38] Total
	[39] No.of cases	[40] Percentage	[41] No.of cases	[42] Percentage	
	[43] R		[44] L		
[45] M	[46] 6	[47] 50%	[48] 6	[49] 50%	[50] 12
[51] F	[52] 6	[53] 54.5%	[54] 5	[55] 45.5%	[56] 11
[57] Total	[58] 12	[59] 52.2%	[60] 11	[61] 47.8%	[62] 23

Except from a unique case where MRA originated from the AA bifurcation. MRA were found bilaterally in 13% (3/23) and unilaterally in 87% (20/23).

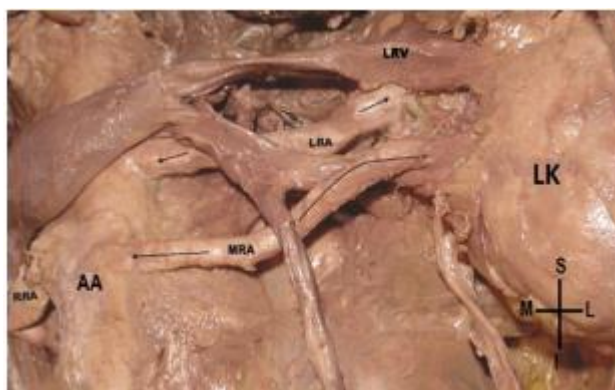

Figure 1 – Multiple renal artery (MRA) arising from the abdominal aorta (AA). RRA – Right renal artery, LRA – Left renal artery, LRV – Left renal vein, LK – Left kidney, S – Superior, I – Inferior, M – Medial, L – Lateral.

Posterior aspect of the renovascular pedicle including the two kidneys and their great vessels.




Figure 2 – Posterior aspect of the renovascular pedicle including the two kidneys and their great vessels. RRA – Right renal artery, 1 – First multiple renal artery, 2 – Second multiple renal artery, AA – Abdominal aorta, IVC – Inferior vena cava, RK – Right kidney, LK – Left kidney, S – Superior, I – Inferior, M – Medial, L – Lateral.

DISCUSSION

RAs (as a pair) supply the kidneys and originate from the lateral wall of AA, at L1 or L2 level, 1.5 cm below the superior mesenteric artery [14]. Usually, the right RA is longer than the left. Each RA runs almost transversely to the renal hilum crossing anterior to the crus of the diaphragm and psoas. The right RA passes behind the inferior vena cava and the right renal vein (RV), whereas the left RA courses behind and above the left RV [15]. During the embryological development, kidneys ascend from the pelvic cavity and take their final position at the lumbar area. Failure of the ascent and persistence of one or more fetal arteries (MRA) may occur [14, 15].

The terminology about the MRA remains obscure and controversial [10, 12]. argued that no established criterion has been used for the arterial aberrance and the term “multiple” described any additional vessel entering the kidney either originated from AA or the main RA. used the terms “main renal”, “aortic superior and inferior polar” and “renal inferior polar” arteries for the single RA. when more than one RAs exist, the additional vessels were called supernumerary, accessory or aberrant and size differences among them exist. named as “aberrant”, the arteries penetrating the kidney in different areas than hilum, whereas as “accessory or supplementary”, the supernumerary vessels penetrating the hilum. that it is incorrect to call these vessels “accessory, aberrant or supernumerary” because they are not extra but essential tissuesustaining, non-anastomotic arteries, corresponding to the segmental branch of a single RA. Sampaio and Passos

CONCLUSIONS

MRA is a common but a significant anatomical variant of the renal vascular system, due to their clinical importance. In our sample, the MRA presence was detected in 11.2% and displayed a greater variation on the left than the right side. Because this abnormality plays an important role in kidney transplantations, in radiological, vascular and urological interventions, a detailed presentation of MRA incidence was conducted, gathering from the literature a large number of relevant studies in order to create a classification according to population, gender, side and specimen.

REFERENCES

- [1] Tarzamni MK, Nezami N, Rashid RJ, Argani H, Hajealioghli P, Ghorashi S, Anatomical differences in the right and left renal arterial patterns, *Folia Morphol (Warsz)*, 2008, 67(2):104–110.
- [2] Awojobi OA, Ogunbiyi OA, Nkposong FO, Unusual relationship of multiple renal arteries, *Urology*, 1983, 21(2):205–206.
- [3] Khamanarong K, Prachaney P, Utraravichien A, Tong-Un T, Sripaoraya K, Anatomy of renal arterial supply, *ClinAnat*, 2004, 17(4):334–336.
- [4] Bakirtas H, Guvence N, Eroglu M, Ure M, Ozok HU, Karabulut I, Gul O, Banli O, Surgical approach to cases with multiple renal arteries in renal transplantation, *UrolInt*, 2006, 76(2):169–172.
- [5] Koplay M, Onbas O, Alper F, Gulcan E, Kantarci M, Multiple renal arteries: variations demonstrated by multidetector computed tomography angiography, *Med PrincPract*, 2010, 19(5):412–414.
- [6] Atasever A, HamdiCelik H, Durgun B, Yilmaz E, Rotated left kidney associated with an accessory renal artery, *J Anat*, 1992, 181(Pt 3):507–508.
- [7] Goscicka D, Szpinda M, Kochan J, AkzessorischeNierenarterienbeimenschlichenFeten, *Ann Anat*, 1996, 178(6):559–563.
- [8] Singh G, Ng YK, Bay BH, Bilateral accessory renal arteries associated with some anomalies of the ovarian arteries: a case study, *ClinAnat*, 1998, 11(6):417–420.
- [9] Bayramoglou A, Demiryurek D, Erbil KM, Bilateral additional renal arteries and an additional right renal vein associated with unrotated kidneys, *Saudi Med J*, 2003, 24(5):535–537.
- [10] Kocabiyik N, Yalçın B, Kılıç C, Kırıcı Y, Ozan H, Accessory renal arteries and an anomalous testicular artery of high origin, *Gulhane Med J*, 2005, 47(2):141–143.
- [11] Deepthinath R, SatheeshaNayak B, Mehta RB, Bhat S, Rodrigues V, Samuel VP, Venkataramana V, Prasad AM, Multiple variations in the paired arteries of the abdominal aorta, *ClinAnat*, 2006, 19(6):566–568.
- [12] Shakeri AB, Tubbs RS, Shoja MM, Pezeshk P, Farahani RM, Khaki AA, Ezzati F, Seyednejad F, Bipolar supernumerary renal artery, *SurgRadiolAnat*, 2007, 29(1):89–92. 13. Gupta A, Gupta R, Singhla RK, The accessory renal arteries: a comparative study in vertebrates with its clinical implications, *J ClinDiagn Res*, 2011, 5(5):970–973.
- [13] Satyanarayana N, Guha R, Nitin V, Praveen G, Datta AK, Sunitha P, Left inferior accessory renal arteries, its embryological basis and clinical significance, *J Coll Med Sci Nepal*, 2011, 7(1):65–68.
- [14] Mamatha H, D’Souza AS, Bilateral accessory renal arteries with a rare origin of the testicular artery: an embryological basis, *J ClinDiagn Res*, 2011, 5(6):1267–1269.